

## **Full spectrum of symptoms of bilateral vestibulopathy needs further investigation – systematic review**

*F. Lucieer<sup>1</sup>, S. Duijn<sup>2</sup>, H. Kingma<sup>1,3</sup>, V. Van Rompaey<sup>4</sup>, A. Pérez Fornos<sup>5</sup>, N. Guinand<sup>5</sup>, J. Ph. Guyot<sup>5</sup>, M. vaHoof<sup>1,3</sup>, R. van de Berg<sup>1,3</sup>*

<sup>1</sup>Department of Otorhinolaryngology and Head and Neck Surgery, Division of Balance Disorders, Maastricht University Medical Center, Maastricht, Netherlands, <sup>2</sup>Faculty of Health, Medicine and Life Sciences, University of Maastricht, Maastricht, Netherlands, <sup>3</sup>Faculty of Physics, Tomsk State Research University, Tomsk, Russian Federation, <sup>4</sup>Department of Otorhinolaryngology and Head & Neck Surgery, Antwerp University Hospital; Faculty of Medicine and Health Sciences, University of Antwerp, <sup>5</sup>Service of Otorhinolaryngology Head and Neck Surgery, Department of Clinical Neurosciences, Geneva University Hospitals Geneva, Switzerland.

### **Introduction and aim**

To systematically review all clinical studies and case reports covering the symptoms reported by patients with bilateral vestibulopathy (BV). This would serve as the first step in establishing a validated Patient Reported Outcome Measure (PROM) for BV.

### **Material and methods**

A systematic search on symptoms reported by BV-patients was performed in Medline and Pubmed by the first two authors, and all publications covering these symptoms were included. Exclusion criteria comprised articles reviews and insufficient details about frequency of occurrence of symptoms.

### **Results**

Fourteen-hundred-and-forty-two (1442) articles were retrieved. In consensus, descriptions of symptoms were classified into 8 common and generic symptoms. Nature and frequency of symptoms in clinical studies and case reports were respectively; imbalance, imbalance worsening in the dark, imbalance on uneven ground, chronic dizziness, oscillopsia and recurrent vertigo. BV could be accompanied by hearing loss and tinnitus. Only a few clinical studies and case reports reported symptoms beyond vestibular and hearing deficits such as limited social activities, depression, concentration and memory impairment, and reduced quality of life in general.

### **Conclusions**

The literature on BV symptomatology mainly focuses on items related to inner ear impairments, while only a few report on broader traits. In fact, none of the clinical studies and case reports reviewed provides a comprehensive overview of BV symptoms. In order to develop a validated PROM, qualitative research, using semi-structured and unstructured interviews, is needed to explore the full spectrum of BV symptoms.

## **Vestibular function and motor performance in infants with a congenital cytomegalovirus infection**

*C. Dhondt<sup>1</sup>, L. Maes<sup>2,3</sup>, I. Dhooge<sup>1</sup>*

<sup>1</sup>Department of Ear Nose Throat, Ghent University, <sup>2</sup>Department of Speech, Language and Hearing Sciences, Ghent University, <sup>3</sup>Department of Otorhinolaryngology, Ghent University Hospital, Ghent, Belgium

### **Introduction and aim**

With an overall prevalence of 0.64%, cytomegalovirus infection is the most common viral congenital infection. Only ten percent of the children with a congenital cytomegalovirus (cCMV) infection show clinical symptoms at birth, but all are at risk of developing long-term sequelae. Sensorineural hearing loss (SNHL) is known to be the most common sequel, resulting from a viral labyrinthitis. cCMV-related labyrinthitis can also affect the vestibular system which can have important consequences on the motor development in young children. Therefore, a longitudinal follow-up of the vestibular and motor function in all cCMV-infected children was initiated in our hospital.

### **Material and methods**

This study describes test results at baseline (<2yr), comprising the video Head Impulse Test (vHIT), rotatory test, cervical Vestibular Evoked Myogenic Potential (cVEMP) test, Alberta Infant Motor Scales and Peabody Developmental Motor Scales-2. Thirty-two children (median age 7.5 months, range 5-15 months) were included and divided into 4 age-matched groups: normal-hearing control (n = 8), asymptomatic cCMV (n = 8), symptomatic normal-hearing cCMV (n = 8) and symptomatic hearing-impaired cCMV (n = 8). Only 1 child showed clinical symptoms at birth but abnormalities on imaging were reported in 13 of 16 symptomatic children. Within the group with SNHL, 3 children had unilateral and 5 bilateral SNHL. Two children had a unilateral cochlear implant at the moment of testing.

### **Results**

Absent cVEMP-responses were only reported in the symptomatic cCMV-group with SNHL in 3 patients (1 bilateral, 2 unilateral). A significant difference was found for the VOR-gain on the vHIT between the four test groups (Kruskal-Wallis Test,  $p = 0.050$ ), in which the lowest gain scores were reported in the symptomatic cCMV-group with SNHL. No significant differences were found between groups for the rotatory test or the motor assessment.

### **Conclusions**

The results of this study suggest that symptomatic hearing-impaired cCMV-infected children are most at risk for vestibular dysfunctions.

## **Twenty-two years of Benign Paroxysmal Positional Vertigo at Sint-Jan Hospital Bruges: a retrospective analysis of 3785 patients**

*S. Vandenbroeck, A.-S. Vinck, B. Lerut*

Department of Otorhinolaryngology, Head and Neck Surgery, Sint-Jan Hospital, Bruges, Belgium

### **Introduction and aim**

Benign paroxysmal positional vertigo (BPPV) is the most common cause of vertigo, with a reported prevalence ranging from 10.7 to 140 per 100.000. In order to get a better understanding of the BPPV population in Belgium, we present a retrospective analysis of twenty-two years of BPPV in our department.

### **Material and methods**

Age, sex, affected canal and affected side were recorded for all BPPV patients from 1995 to 2016. Data from telephone follow-up assessment three days after canal reposition maneuvers (CRM) was documented from 2012 to 2016. Results were analysed and compared with the literature.

### **Results**

Retrospective analysis showed a total of 3785 patients, of which 1140 (30.54%) were male and 2646 (69.46%) were female (F/M ratio 2.32). Posterior canal BPPV was the most frequent, with 2759 affected patients (72.89%). 701 patients had horizontal canal BPPV (18.52%), of which the geotropic type was most frequent (478 geotropic (68.2%) vs. 223 ageotropic (31.8%)). Anterior canal BPPV and multiple canal BPPV occurred less frequently, with 155 (4.10%) and 168 (4.4%) affected patients respectively. Telephone assessment after three days showed complete resolution of symptoms in 813 of 1468 patients (55.38%). 655 patients had various persistent symptoms, ranging from lightheadedness to rotatory vertigo. However, 126 (8.58% of total) patients preferred to await further effect of the initial CRM and did not return with persistent complaints. Also, 207 (14.10% of total) of patients with various persistent symptoms had no evidence for remaining BPPV at follow-up testing. Ultimately, only 322 (21.93% of total) patients with persistent symptoms did have a positive BPPV testing at the return visit.

### **Conclusions**

We present the largest Belgian cohort of BPPV patients to date. Our findings are consistent with those found in the literature. However, presumably due to routine use of video goggles, a higher percentage of anterior canal BPPV was observed, suggesting an underestimation of this entity.

## **Impact of bilateral vestibulopathy on spatial and non-spatial cognition: a systematic review**

*B. Dobbels<sup>1,2</sup>, O. Peetermans<sup>2</sup>, B. Boon<sup>2</sup>, G. Mertens<sup>1,2</sup>, P. Van de Heyning<sup>1,2</sup> V. Van Rompaey<sup>1,2</sup>*

<sup>1</sup>Dept. Otorhinolaryngology & Head and Neck Surgery, Antwerp University Hospital, Belgium, <sup>2</sup>Faculty of Medicine and Health Sciences, University of Antwerp, Belgium

### **Introduction and aim**

Hearing loss is considered an independent risk factor for dementia. Growing evidence in animal and human studies suggest that not only hearing loss, but also vestibular loss might result in cognitive deficits. The relation between cognition and the vestibular system is best studied in patients with bilateral vestibulopathy (BV), who suffer from a partial or complete loss of function of the peripheral vestibular apparatus. In this review our aim is to evaluate the presence of spatial and non-spatial cognitive deficits in BV patients.

### **Material and methods**

We performed a systematic review according to the PRISMA guidelines on published studies considering cognitive performances in BV patients. Three independent researchers explored Medline and the Cochrane Library. Studies reporting on cognition in BV patients were included according to a predefined eligibility assessment. The methodological quality of each article was evaluated using a quality assessment tool, compiled by the National Institute of Health. Data of the patients' characteristics and their cognitive outcomes were extracted from the included articles.

### **Results**

Seven studies reporting on 73 BV patients matched the inclusion criteria. Overall, the methodology of the included papers was of good quality. Criteria for including BV patients varied widely across the studies. Cognitive domains evaluated in BV patients included visuospatial abilities, memory, language, attention and executive function. Only social cognition seem to be never investigated before in a BV population. The applied test modalities display a wide heterogeneity. Only in one of the seven studies hearing performance of the included patients was briefly described. Nearly all studies demonstrated a significant impairment of spatial cognition in BV patients. Only recent papers investigated other cognitive domains than spatial cognition. In these papers a negative impact of BV on the other cognitive domains was also described.

### **Conclusions**

Strong evidence exists that BV patients suffer from impaired spatial cognition. Recent studies even suggest impairment in other cognitive domains than spatial cognition. However, in all previous studies, conclusions on the link between cognitive performance and BV were drawn without taken hearing loss into consideration as a possible cause of the cognitive impairment. Future prospective studies are necessary to establish the link between hearing loss, vestibular loss and cognition.

## **On the effect of noisy galvanic vestibular stimulation on dynamic visual acuity in bilateral vestibulopathy**

*N. Herssens<sup>1,2</sup>, W. Saeys<sup>1,3</sup>, L. Vereeck<sup>1</sup>, B. Dobbels<sup>4,5</sup>, V. Van Rompaey<sup>4,5</sup>, A. Halleman<sup>1,2</sup>*

<sup>1</sup>Dept. Rehabilitation Sciences and Physiotherapy, Faculty of Medicine and Health Sciences, University of Antwerp, <sup>2</sup>Multidisciplinary Motor Centre Antwerp, University of Antwerp, <sup>3</sup>Rehabilitation Hospital RevArte, Antwerp, <sup>4</sup>Dept. Otorhinolaryngology and Head & Neck Surgery, Antwerp University Hospital, <sup>5</sup>Dept. Translational Neurosciences, Faculty of Medicine and Health Sciences, University of Antwerp

### **Introduction and aim**

The vestibular system provides a gravito-inertial reference for balance control, which is failing in patients with bilateral vestibulopathy (BV). Complete or partial loss of vestibular function affects the vestibulospinal and vestibulo-ocular reflexes which play an important role in maintaining stable posture and gaze. Recent studies have evaluated the potential of noisy galvanic vestibular stimulation (nGVS) to upregulate primary vestibular afferent and hair cell activity by means of stochastic resonance. Improvement in vestibular balance control and postural stability has been observed, however, the impact of nGVS on gaze stabilization has not been investigated. Therefore, the primary aim was to study the effect of nGVS on dynamic visual acuity (DVA) in BV patients.

### **Material and methods**

Nine BV patients were included according to the Bárány society diagnostic criteria. Gaze stabilization was tested with the DVA-test during treadmill locomotion, with and without nGVS in a randomized order and patients blinded to the stimulation protocol. Additionally, health-related quality of life was evaluated through the Dizziness Handicap Inventory (DHI). The correlation between DHI (sub)scores and change in DVA-performance was studied.

### **Results**

Age ranged from 28.13 to 73.27 years (5:4 male-female ratio). Etiologies included idiopathic BV (n = 2), gentamicin toxicity (n = 2), auto-immune inner ear disorder (n = 2), meningitis (n = 2) and bilateral vestibular neuritis (n = 1). Total DHI scores ranged from 0 (no self-perceived disability) to 84 (severe self-perceived disability). DVA-performance remained stable in 5/9 patients, three patients performed better with nGVS (change in DVA-performance >0.10 logMAR) and one patient performed worse. The “Physical” DHI subscore demonstrated a strong correlation ( $r = -0.684$ ,  $p = 0,042$ ) with DVA improvement during nGVS.

### **Conclusion**

This pilot study provides preliminary data suggesting that noisy galvanic vestibular stimulation could be effective in improving gaze stabilization in a subset of patients suffering from bilateral vestibulopathy.

## Machine learning can distinguish inner ears affected by Ménière's disease from healthy controls

*M.C.J. de Wit<sup>1</sup>, M. van Hoof<sup>1</sup>, E.L. van den Burg<sup>1</sup>, H. Kingma<sup>1,4</sup>, A.A. Postma<sup>2</sup>, A.M.L. Janssen<sup>3</sup>, M. Bilderbeek-Beckers<sup>5</sup>, A. Laurent<sup>5</sup>, E. Theunissen<sup>6</sup>, P. Dammeijer<sup>6</sup>, V. Van Rompaey<sup>7,8</sup>, Tj. D. Bruintjes<sup>9</sup>, R. van de Berg<sup>1,4</sup>*

<sup>1</sup>Dept. Otorhinolaryngology and Head and Neck Surgery, Maastricht University Medical Center, <sup>2</sup>Dept. Radiology, Maastricht University Medical Center, <sup>3</sup>Dept. Methodology and Statistics, School for Public Health and Primary Care (CAPHRI), Maastricht University, <sup>4</sup>Faculty of Physics, Tomsk State University, Russian Federation, <sup>5</sup>Dept. Radiology, VieCuri Medical Center, Venlo, <sup>6</sup>Dept. Otorhinolaryngology, VieCuri Medical Center, Venlo, <sup>7</sup>Faculty of Medicine and Health Sciences, University of Antwerp, <sup>8</sup>Dept. Otorhinolaryngology and Head & Neck Surgery, Antwerp University Hospital, <sup>9</sup>Apeldoorns Duizeligheidscentrum, Apeldoorn

### Introduction and aim

Ménière's disease (MD) is characterized by non-exclusive physical symptoms and signs, relying on diagnostic criteria that enable a definite and probable diagnosis. The pathophysiological hallmark involves endolymphatic hydrops, which can, however, also be observed in patients with other otovestibular disorders or without the associated clinical symptoms. Recently it has been shown (Aerts et al. 2014) that intensities in conventional medical imaging can be numerically processed using data-characterization algorithms (radiomics) to enable feature quantification beyond the human eye for prognostic purposes. The primary aim of this project was to investigate if conventional MRI scans of the inner ear contains radiomics features that can specifically be attributed to MD and if machine learning would be able to discriminate subjects with and without definite MD.

### Material and methods

A retrospective study was performed in Maastricht University Medical Center, VieCuri hospital (Venlo), the Antwerp University Hospital and the Apeldoorn Dizziness center. Patients with definite MD according to the American Academy of Otolaryngology-Head and Neck Surgery criteria were included. The control group consisted of patients with idiopathic asymmetrical sensorineural hearing loss, i.e. the unaffected inner ear as control. The T2-weighted MRI scans were characterized by a set of primary and secondary radiomics features which were analyzed by the built-in machine learning package of Wolfram Mathematica 11.2 (Wolfram Research Inc., USA). Statistical testing was performed with a binomial test.

### Results

The prevalence of MD in the 288 included patients was 44%. The randomly mixed training set consisted of 213 scans. The separate randomly mixed validation set consisted of 50 scans in which a statistically significant accuracy of  $80 \pm 6\%$  was achieved ( $p = 0.005$ ).

### Conclusions

Machine learning can distinguish inner ears affected by definite MD accurately from healthy controls by using semiautomatic volumetric segmentation and radiomics features of conventional MRIs obtained in different centers.

## **Altered circadian locomotor activity after acute otovestibular failure in rodents**

*V. Van Rompaey<sup>1,2</sup>, S. Missault<sup>1</sup>, K. Szewczyk<sup>1</sup>, P. Van de Heyning<sup>1,2</sup>, P. De Deyn<sup>3,4,5</sup>, D. Van Dam<sup>3,5</sup>*

<sup>1</sup>Faculty of Medicine and Health Sciences, University of Antwerp, Belgium, <sup>2</sup>Dept. Otorhinolaryngology & Head and Neck Surgery, Antwerp University Hospital, Belgium, <sup>3</sup>Dept. Neurology and Alzheimer research center, University of Groningen and University Medical Center Groningen, The Netherlands, <sup>4</sup>Dept. Neurology/Memory clinic, ZNA Middelheim, Antwerp, Belgium, <sup>5</sup>Laboratory of Neurochemistry and Behaviour, Institute Born-Bunge, Faculty of Pharmaceutical, Biomedical and Veterinary Sciences, University of Antwerp, Belgium

### **Introduction and aim**

Similar to Alzheimer's disease, diurnal rhythm disturbances and cognitive dysfunction have been observed in rodent models of bilateral vestibulopathy (BV). Sleep and circadian disruption can impair hippocampal neurogenesis and subsequently impair hippocampus-dependent learning and memory. Recent insights have explored the connection between the vestibular system and hypothalamic regulation of circadian rhythms. The aim of this study was to evaluate circadian patterns of locomotor activity before and after acute otovestibular failure in 129S1/SvImJ mice.

### **Materials and methods**

We evaluated adult 129S1/SvImJ mice, purchased from Charles River - Jackson Laboratories (JAX), 1 week before and 1 week after allylnitrile exposure (p.o. in 6 ml/kg of corn oil). Vestibular function as evaluated with the validated score reported by Jordi Llorens. Hearing was evaluated through auditory brainstem recording (ABR) under inhalation anaesthesia.

Cage activity was evaluated continuously over a period of 47 hours, including a 12-hour dark phase (when the animal should be more active) and a 12-hour light phase (when the animal should be less active). Ambulatory movements (e.g. animal is walking through cage) included multiple infrared beams crossed sequentially. Fine movements (e.g. animal is grooming) included one infrared beam disrupted multiple times. Statistical analysis was performed using a mixed model with random effects and fixed effects.

### **Results**

Allylnitrile exposure resulted in acute-onset and permanent vestibular failure and profound sensorineural hearing loss. A statistically significant interaction was observed on ambulatory ( $p < 0.05$ ) and fine movements ( $p < 0.0001$ ) when comparing measurements before versus after allylnitrile exposure and comparing with the control group.

### **Conclusion**

Our findings support the hypothesis that the vestibular system has an influence, at least short-term, on daily rhythm homeostasis in rodents. This circadian rhythm disturbance might play a role in decreased adult hippocampal neurogenesis and spatial cognitive decline.



## On the symptomatology, MRI characteristics and management in a large cohort of vestibular schwannoma patients

E. Greant<sup>1</sup>, B. Ihtijarevic<sup>1</sup>, T. Menovsky<sup>2,3</sup>, P. Van de Heyning<sup>1,2</sup>, V. Van Rompaey<sup>1,2</sup>

<sup>1</sup>Dept. Otorhinolaryngology & Head and Neck Surgery, Antwerp University Hospital, Belgium, <sup>2</sup>Faculty of Medicine and Health Sciences, University of Antwerp <sup>3</sup>Dept. Neurosurgery, Antwerp University Hospital, Belgium

### Introduction and aim

Vestibular schwannomas are benign tumours arising from the vestibulocochlear nerve. Vertigo, hearing loss, tinnitus and ear fullness are the most common symptoms reported among these patients. An MRI-scan of the cerebellopontine angle (CPA) typically leads to the diagnosis of the vestibular schwannoma. Sometimes, it is an incidental finding on the MRI performed for a different indication. Since there is a significant amount of stable tumors, active treatment (including radiotherapy and microsurgical resection) is often not indicated at presentation. A (passive) treatment option is the wait-and-scan policy, in which serial MRIs are performed to measure tumor growth.

The aim of this study was to describe the symptomatology, MRI characteristics and management among patients diagnosed with a sporadic vestibular schwannoma.

### Material and methods

A retrospective study was performed on 334 patients diagnosed with a unilateral sporadic vestibular schwannoma at a university tertiary referral center for neurotology and skull base surgery. Demographic data and presenting symptoms were retrieved from the medical history while maximal diameter in the CPA, the presence of cystic components and/or brainstem compression were studied on the first MRI performed in each patient. Tumor size was classified using the 2001 *Consensus Meeting on Acoustic Neuroma* guidelines: intracanalicular (not reaching the CPA), small (1-10 mm in the CPA), medium (11-20 mm in the CPA), moderately large (21-30 mm in the CPA), large (31-40 mm in the CPA) and giant (over 40 mm in the CPA). Patients with primary inner ear schwannomas, neurofibromatosis type 2, meningiomas as well as patients already actively treated elsewhere (by radiotherapy, subtotal resection or gross total resection) were excluded from this study.

### Results

Age ranged from 18 to 84 years with a mean age of 52 years (51% male, 49 % female). More than half of patients (54%) complained of ipsilateral subjective hearing loss. Tinnitus was present in 38% of patients, while 29% experienced vertigo and only 13% had ear fullness. A cystic component was observed in 21%, while brainstem contact or compression was found in 43%. Tumor size included 16.8% intracanalicular, 20% small, 37% medium, 15.3% moderately large, 7.2% large and 2.8% giant tumours. Wait-and-scan was advised in 32.7%, 10.6% was scheduled for microsurgical resection after initial wait-and-scan policy, surgery was advised at presentation in 52.6% and radiotherapy was advised in 4.1%.

### Conclusions

Management and treatment strategies are based upon presenting symptoms, patient factors and MRI features. In our series, sporadic vestibular schwannomas are diagnosed at all ages and mainly present with hearing loss, tinnitus and/or vertigo. A significant amount of tumors are medium-sized or larger and already touch the brainstem at presentation.



## **CO<sub>2</sub> laser myringotomy efficacy in adults with otitis media with effusion: a 5-year retrospective study**

*M. Verhasselt, P. Bisschop, H. Kabtouri*

Department of Otorhinolaryngology, Brugmann University Hospital, Brussels, Belgium

### **Introduction and aim**

Surgical management of otitis media with effusion (OME), after conservative therapy failure, most commonly relies on incision myringotomy and ventilation tube placement. In the paediatric population, laser myringotomy has been demonstrated as a safe and easy alternative to ventilation tubes for short term middle-ear ventilation. In adults however, few studies report cure rates of this procedure in secretory otitis. In the present study, we aim to determine these rates as well as the mean perforation closing time.

### **Material and methods**

This monocentric retrospective study includes 26 patients who underwent laser myringotomy for OME from January 2013 until end of November 2017. CO<sub>2</sub> laser myringotomy was performed under local anaesthesia. Procedure success was assessed through otologic examination, tone audiometry and tympanometry. In case of procedure failure, further ventilation tube placement was considered.

### **Results**

16 patients out of the total 26 included showed OME resolution, representing thus a 61% success rate. In the cases where laser myringotomy failed, 3 patients needed further ventilation tube placement. The other 7 patients with persistent OME were lost to follow-up. Mean perforation closure time was 28 days (range 7-52 days).

### **Conclusion**

Laser myringotomy is a good alternative to ventilation tube placement for short-term middle ear ventilation in adults with OME.

## **Long-term follow-up of the Chorda Tympani function after middle ear surgery**

*M. Claerhout<sup>1,2</sup>, P.J. Leupe<sup>2</sup>, N. Verhaert<sup>1</sup>, C. Desloovere<sup>1</sup>*

<sup>1</sup>Department of Oto- Rhino- Laryngology, Head and Neck surgery, KU Leuven, Belgium, <sup>2</sup>Department of Oto- Rhino- Laryngology, Head and Neck surgery, AZ Delta Roeselare, Belgium

### **Introduction and aim**

The Chorda Tympani runs uncovered through the middle ear and can be injured during surgery due to thermal damage, drying, transection or traction of the nerve. The aim of this study is to document the incidence of postoperative taste problems after middle ear surgery with a long-term follow-up to assess evolution. Secondary goals were to evaluate the influence of the pathology and the degree of the Chorda Tympani manipulation on its function.

### **Materials and methods**

With a questionnaire, we prospectively assessed the subjective taste of 40 patients undergoing middle ear surgery. We calculated chemical taste scores for the operated and contralateral side using a chemical taste test protocol. The intraoperative manipulation of the Chorda Tympani was also documented.

### **Results**

A significant correlation between the chemical taste scores on the operated side and the indicated subjective taste was found preoperatively and short-term postoperatively. No correlation was found three years after the surgery. A significant correlation between the chemical taste score at the operated side and the degree of Chorda Tympani damage was also found. The chemical taste score on the operated side decreased significantly if the Chorda Tympani was slightly touched or stretched without visible damage.

### **Conclusions**

Our results show that a reduction in subjective taste is a relatively frequent yet transient complication after middle ear surgery. Compensation mechanisms other than a (partial) Chorda Tympani recovery co-exist and could explain the loss of correlation between chemical taste tests and subjective taste evaluation long-term postoperatively. Significant change of chemical taste scores after Chorda Tympani manipulation, suggests that an intraoperative Chorda Tympani evaluation could be a good predictor of postoperative taste reduction.

## **Long-term follow-up of the Chorda Tympani function after middle ear surgery**

M. Claerhout<sup>1,2</sup>, P.J. Leupe<sup>2</sup>, N. Verhaert<sup>1</sup>, C. Desloovere<sup>1</sup>

<sup>1</sup>Department of Oto- Rhino- Laryngology, Head and Neck surgery, KU Leuven, Belgium, <sup>2</sup>Department of Oto- Rhino- Laryngology, Head and Neck surgery, AZ Delta Roeselare, Belgium

### **Introduction and aim**

The Chorda Tympani runs uncovered through the middle ear and can be injured during surgery due to thermal damage, drying, transection or traction of the nerve. The aim of this study is to document the incidence of postoperative taste problems after middle ear surgery with a long-term follow-up to assess evolution. Secondary goals were to evaluate the influence of the pathology and the degree of the Chorda Tympani manipulation on its function.

### **Materials and methods**

With a questionnaire, we prospectively assessed the subjective taste of 40 patients undergoing middle ear surgery. We calculated chemical taste scores for the operated and contralateral side using a chemical taste test protocol. The intraoperative manipulation of the Chorda Tympani was also documented.

### **Results**

A significant correlation between the chemical taste scores on the operated side and the indicated subjective taste was found preoperatively and short-term postoperatively. No correlation was found three years after the surgery. A significant correlation between the chemical taste score at the operated side and the degree of Chorda Tympani damage was also found. The chemical taste score on the operated side decreased significantly if the Chorda Tympani was slightly touched or stretched without visible damage.

### **Conclusions**

Our results show that a reduction in subjective taste is a relatively frequent yet transient complication after middle ear surgery. Compensation mechanisms other than a (partial) Chorda Tympani recovery co-exist and could explain the loss of correlation between chemical taste tests and subjective taste evaluation long-term postoperatively. Significant change of chemical taste scores after Chorda Tympani manipulation, suggests that an intraoperative Chorda Tympani evaluation could be a good predictor of postoperative taste reduction.

## **Stapes surgery for otosclerosis in patients presenting with mixed hearing loss**

*D.Thys, C. Salmon, S. Barriat and P.P. Lefebvre*

Department of Otorhinolaryngology, University of Liège, Belgium

### **Introduction and aim**

In this article, we wanted to evaluate the efficacy of stapes surgery in patients presenting a pre-operative mixed hearing loss (bone conduction (BC)  $\geq$  40dB ; 40dB < air conduction (AC) < 85dB)

### **Material and methods**

30 patients (and 32 operated ears) with mixed hearing loss undergoing primary stapedotomy were evaluated. Audiometric parameters were assessed before and after surgery. Controlateral thresholds were also reported. The need for hearing aid after surgery, and its impact on quality of life were also measured.

### **Results**

Air conduction threshold and articulation function (percentage of word recognition score for 40, 55 and 70dB) were significantly improved after stapes surgery. Only 16,6% of the patients needed hearing aid (HA) after surgery and reported to be satisfied with this aid.

### **Conclusion**

Stapes surgery improved the auditory function in mixed hearing loss, allowing most of our patients to delay the need of HA without worsening quality of life.

## **Why is it useful to test the audiovisual integration in deaf patients?**

*J. Wathour<sup>1</sup>, E. Nyssen<sup>2</sup>, C. Mullender<sup>2</sup>, M. Decat<sup>1</sup>, N. Deggouj<sup>1</sup>*

<sup>1</sup>Cliniques universitaires Saint-Luc, Bruxelles, <sup>2</sup>Université Catholique de Louvain-La-Neuve

### **Introduction and aim**

Classical speech intelligibility tests are done only on base of auditory stimulation. It is therefore important to test the speech intelligibility like in real life that means with auditory and visual conditions. The auditory and visual words could be presented in a congruent and incongruent condition. In this second condition, our brain will not content to contemplate what our senses transmit to it but it will integrate the signals to build its own perception of the word that does not always correspond to reality (like in the hallucinatory perceptions of the McGurk effect). Currently, there was no clearly established test evaluating the lip reading and the audiovisual profile of patients. In this aim, we have developed an audio-visual test, the DEWA in order to assess the age and hearing loss effect on the audiovisual perception of speech in congruent and incongruent conditions.

### **Material and methods**

“DEWA” test is a DVD including 4 phonemically and spectrally balanced lists of monosyllabic words, presented in 4 conditions: Visual, Incongruent Audiovisual, Auditory and Congruent AudioVisual. It was administrated to children and adults hearing and deaf.

### **Results**

Congruent audiovisual condition is the easiest and the most resistant condition with increasing age for hearing and deaf subjects. In the auditory condition, the children present a positive age-effect with an improvement of their speech intelligibility with age. A negative age-effect is present in the more aged adults (> 60 years). In the visual condition, a ‘maturational effect’ is found in normal hearing and CI children. In incongruent audiovisual condition, in hearing population, the younger and the older subjects give more weight to the auditory information even if it is not pertinent. In deaf population, older tend to provide equally visual, auditory or integrated percepts.

### **Conclusions**

Recent theory of physiology of language posits a dual pathway ventral/dorsal organization of speech perception (such as vision). Our younger and older subjects give more importance to auditory information. Is it due to difference in access and use of the dorsal and ventral stream ?

# Audiometric findings in elderly of 80 years and older and the potential link between audiometric parameters and cognition

*K. De Raedemaeker, I. Foulon, F. Gordts*

Universitair Ziekenhuis Brussel

## Introduction and aim

We propose reference values of hearing thresholds in elderly people of 80 years and older, as there are no ISO values available in this age category. Furthermore we will try to determine a link between hearingloss and cognition.

## Material and methods

A descriptive, prospective, ongoing study testing pure-tone and speech audiometry in healthy participants of 80 years and older. One hundred eighty one elderly were asked to participated in the BUTTERFLY gerontological study. Speech reception thresholds (SRT), Pure-tone average (PTA), Low- and High frequency average were calculated for the best ear and compared according to gender, age group, hearing aid usage and presence of tinnitus. The BIAP classification was used to determine the prevalence of hearingloss (PTA > 20 dB HL) in our population.

## Results

One hundred fifty one patients, with a mean age of 82.4 years, were included. The prevalence of hearingloss was 90.7%. In the low frequencies males had better hearing than females. This difference disappeared with increasing frequency and age due to a steeper down sloping curve and a significant deterioration with age on every frequency in males. Females only deteriorated significantly with age in the high frequencies with a more gradually sloping curve. Consequently, in the high frequencies males had poorer hearing than females at every age above 80 years. Up until now the temporary results haven't showed any link between hearing loss and cognition.

## Conclusion

Our study demonstrates that the vast majority of the elderly of 80 years and older suffer from hearing loss (90.7%). The proposed reference values can be used in clinical practice to evaluate the hearing of this vulnerable population.

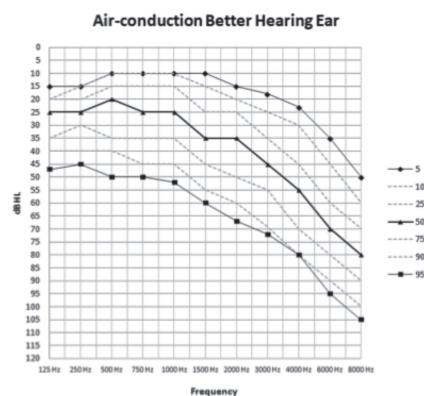

Figure 1.

Proposed reference values of hearing thresholds in elderly people of 80 years and older: Percentile distribution of the air-conduction thresholds (dB HL) in the better hearing ear of all participants.

## **Auditory functional connectivity in King Kopetzki patients: a prospective and controlled magnetoencephalographic study**

*C. Ducène<sup>1,2</sup>, V. Wens<sup>1</sup>, M. Bourguignon<sup>1</sup>, B. Marty<sup>1</sup>, X. De Tiège<sup>1</sup>, M. Vander Ghinst<sup>1,3</sup>*

<sup>1</sup>Laboratoire de cartographie fonctionnelle du cerveau de l'ULB, CUB Erasme, Brussels, Belgium, <sup>2</sup>ENT department, CHU Saint-Pierre, Brussels, Belgium, <sup>3</sup>ENT department, CUB Erasme, Brussels, Belgium

### **Introduction and aim**

King Kopetzky syndrome (KKS) is defined by poor speech-in-noise (SIN) understanding despite normal tonal audiogram thresholds. So far, no specific aetiologies have been clearly identified and subtle abnormalities in the peripheral auditory system do not seem to account for the discomfort of the patients. In this study, we tested the hypothesis that KKS is related to central dysfunctions. Therefore, using magnetoencephalography (MEG), we compared the cerebral functional connectivity (FC) between patients with KKS and healthy controls.

### **Material and methods**

Fourteen native French-speaking patients with KKS and their age- and sex-matched healthy controls were recruited. They had normal otomicroscopy and tonal audiogram thresholds. Speech audiometry with and without background noise was tested. During the MEG session, cerebral activity was recorded in a resting-state condition and in two listening conditions (speech randomly presented with or without a background babble noise with a signal to noise ratio of 0). FC was studied by performing a correlation analysis with seeds chosen in the left and right primary auditory cortices within  $\alpha$ ,  $\beta$ , and  $\theta$  frequency bands for the three conditions (resting state, speech with/without noise).

### **Results**

As expected, patients' speech audiometries statistically differed from controls' ones only when a background noise was added ( $p^* = 0,0004$ ). By contrasting subjects' and patients' maps, analyses revealed that FC patterns differed significantly between those two groups for each frequency bands in several areas, notably in regions involved in auditory and speech processing, in resting-states as well as in speech conditions.

### **Conclusions**

As the brain rhythms are thought to be fundamental to code the multi-timescale of language, the variations observed between groups in various frequency bands unmask intrinsic modifications of speech processing. This study highlights specific differences in terms of neural correlates among patients with KKS, which might be classified as a language processing disease.



## School performance of early implanted children with cochlear implants in mainstream education in Flanders

S. Krijger<sup>1</sup>, P. Govaerts<sup>1,2</sup>, I. Dhooge<sup>1,3</sup>

<sup>1</sup>Department of Otorhinolaryngology, Ghent University, Belgium, <sup>2</sup>The Eargroup, Deurne-Antwerp, Belgium, <sup>3</sup>Ghent University Hospital, Ghent, Belgium

### Introduction and aim

Although the majority of the early implanted CI children in Flanders are being educated in mainstream schools little is known about their school performance.

The aim of this study was to determine whether early implanted children, who were implanted before the age of 2, develop age appropriate academic outcomes in their last year of elementary school.

### Materials and method

The academic outcomes were derived from two tests that are annually developed by the school groups (OVSG and IDP tests). Nineteen early implanted CI students were included in this study, all of them enrolled in mainstream education. Of these students 10 IDP and 2 OVSG tests could be obtained. Data of the IDP tests (N = 10) were used for further statistical analysis and were compared to the results of their NH peers (N = 208).

### Results

Mean results (%) and standard deviations of both NH en CI students were summarized in the table below:

	NH students	CI students	Statistical significant difference
Writing	78 (15.7)	81 (13.0)	
Reading	68 (20.1)	72 (16.0)	
Listening	73 (18.7)	60 (18.9)	$p < .05$
Grammar	71 (21.6)	67 (23.6)	
Algebra	72 (19.5)	67 (18.9)	
Properties of numbers	75 (23.0)	64 (27.5)	
Geometry	67 (21.6)	54 (25.5)	
Measurement	64 (23.3)	82 (22.5)	

### Conclusions

Results show that the average academic outcomes of the CI students were within the normal range of normal hearing students, except for one test, i.e. the listening test. The listening test examines the listening comprehension of the student via audio recordings. Listening to audio recordings may cause listening problems for the CI student hindering their performance on such a test. Further research is necessary to determine how this influences their global listening skills at school and how this may affect their further academic career.

## **Outcome after surgery for pediatric cholesteatoma: a retrospective analysis with long-term follow-up**

*S. Mattheeuws, H. Van Hoecke, I. Dhooge*

Department of Otorhinolaryngology, Ghent University Hospital, Ghent, Belgium

### **Introduction and aim**

Management of pediatric cholesteatoma is generally considered as challenging because of the biologically more aggressive phenotype and presence of a developing mastoid. We manage most pediatric cholesteatoma cases at our department by a 2-stage surgical approach. The aim of this work was to evaluate the results of cholesteatoma surgery in our pediatric population by means of recidivism (recurrent and residual disease) and hearing outcome and to analyze influence of the different types and stages of cholesteatoma and the different surgical techniques on the outcome parameters.

### **Material and Methods**

79 ears in 76 children, aged <17 years with acquired cholesteatoma that underwent primary surgery at our department between 2007 and 2014 were extracted from our database. Minimum follow up period was 3 years after the first surgery. Pre-, per- and postoperative parameters were retrospectively reported from the medical patient files. Descriptive analyses were performed as well as regression analyses to evaluate the impact of patient-, disease and procedure-related parameters on the surgical outcome.

### **Results and conclusions**

Our study population is characterized by a male-to-female ratio of 54:25 and a mean age of 8.75 years with a mean follow-up time of 5.63 years. 58.1% of the cases were pars tensa cholesteatoma, 30.6% pars flaccida and 11.3% combined cholesteatoma. The cholesteatoma were staged as class I, II, II and IV according to the EANO/JOS Staging in respectively 24.2%, 71.0%, 3.2% and 1.6% of the cases. A dry ear was obtained in 98.4%. The hearing outcome was considered as functional in 82.5% of the treated ears. The overall recidivism rate was 35.5% after the first procedure which implies the necessity of the second look procedure. Preliminary results will be supplemented with ongoing analyses.

## **Safety of the bony obliteration tympanoplasty for cholesteatoma with labyrinthine fistula**

*Q. Roggeman, J. van Dinther, R. Vanspauwen, A. Zarowski, T. Somers, E. Offeciers*

European Institute for ORL-HNS, Department of ENT-HNS, Sint Augustinus Hospital GZA, Antwerp

### **Introduction and aim**

To evaluate safety (residual or recurrent disease), hygiene and hearing results (inner ear function) in cholesteatoma surgery complicated with labyrinthine fistula using the bony obliteration technique.

### **Material and methods**

The study design is a retrospective cohort study consisting of 35 ears undergoing surgery with bony obliteration technique for chronic otitis media with cholesteatoma complicated with a labyrinthine fistula between 2005 and 2016. Patient characteristics, pre- and postoperative bone conduction thresholds, and residual or recurrent disease were reviewed. Pure Tone Average (PTA) was used as means of audiometric evaluation. Additionally AHEP (Amsterdam Hearing Evaluation Plot) was used to plot and analyse individual patients results.

### **Results**

In 23 cases patients were male, in 12 female. 18 were primary cases, whereas 17 were revisions. All patients presented with a fistula of the lateral semi-circular canal. In 6 cases a second fistula was present elsewhere in the labyrinth. In one case a iatrogenic fistula occurred due to surgery. We found that no significant change and in particular no significant deterioration of bone conduction is associated with the use of the bony obliteration technique in ears with a labyrinthine fistula. Average pre- and postoperative bone conduction for primary and revision cases as well as for total cases were respectively: 22.04 and 18.61, 24.02 and 23.14, and 23.0 and 20.81 dB HL. Three cases showed an open labyrinth, in comparison to a fistula with an intact endostium in all the others. Bone conduction thresholds stayed equally stable in open as in intact fistulas. Two cases presented with residual disease located at the lateral semi-circular canal.

### *Conclusion*

In this study of the bony obliteration tympanoplasty for cholesteatoma surgery involving labyrinthine fistulas no negative impact on the inner ear hearing function could be found. In two cases residual disease was found during the follow-up at the site of dehiscence of the lateral semi-circular canal.

## **Quality of life in patients with Mercke tympanoplasty and bony obliteration technique using COMQ12 – a disease specific PROM**

*W. Baetens, A. Zarowski, E. Offeciers, T. Somers, J. van Dinther*

European Institute ORL – Sint-Augustinus, Wilrijk

### **Introduction and aim**

It is commonly known that the chronic otitis media (COM) problems have an impact on the quality of life (QOL) of patients. In this study, we want to investigate the short-term effect of Mercke tympanoplasty with bony obliteration technique (BOT) on the QOL in patients with COM. A few years ago the Dutch COMQ12 was validated. This questionnaire investigates the symptom severity, life and work impact and health impact of COM in the past 6 months. Our goal was to assess patient reported health and impact on work and social life following surgery using a disease specific patient related outcome measure questionnaire.

### **Materials and methods**

Patients with COM were asked to complete the COMQ12 pre-operatively, 6 months post-operatively and after 1 year post-operatively.

### **Results**

A total of 36 patients were included: 18 men and 18 women. The mean age is 35,24 years. Calculating the median of each question and comparing with the pre-operative group, we notice a decrease of the complaints on all questions. The raw average of the total score of the COMQ12 for the pre-operative, post-operative 6 months and after 1 year post-operatively is respectively 25,58 points, 14,2 points and 11,47 points. The largest decrease is noticeable in the first months after surgery.

### **Conclusion**

Using the COMQ12 in our population (Patients with COM and Mercke tympanoplasty with BOT), we have a clear decrease in the severity of the symptoms, life and work impact and health care after surgery.

## **Middle ear problems in children with cleft lip and/or palate**

*F. Dochy, E. Vanheule, E. De Leenheer, I. Dhooge, H. Van Hoecke*

### **Introduction and aim**

The aim of this study is to analyse the incidence of middle ear problems in the different age groups of children with cleft lip and/or palate.

### **Material and methods**

Data for this cross-sectional case control study were collected from the patient files of cleft children visiting the CLP-team of the Ghent University Hospital between May 2016 and April 2017. Descriptive statistics were tested with IBM SPSS statistic data editor 25.

### **Results**

In total, 201 children, aged 0-18 years, were registered in the database, 35 with a cleft lip (CL), 58 with a cleft palate (CP) and 108 with a cleft lip and palate (CLP). Of the 166 C(L)P children, 126 (75.9%) received at least one VT (ventilation tube). The presence of OME (otitis media with effusion) and VT was most common between the age of 3 and 5 years old with a point prevalence of 66.7%. The mean age of the first VT placement was 2.1 years and 69% of the children receiving VT, underwent multiple placements. The placement of long-term ventilation increased in older children.

Long-term complications included tympanic perforation, atelectasis or cholesteatoma. Nine (5.4%) of the C(L)P children had undergone a tympanoplasty and 6 (3.6%) a mastoidectomy.

Gender, the presence of a craniofacial syndrome, severity of the cleft, early placement of VT during palatoplasty and the type of VT did not independently affect the middle ear status nor the risk on middle ear complications.

### **Conclusion**

OME remains an important concern in children with a cleft palate and is most prevalent at toddler age, which is crucial in the development of speech and language skills. A significant proportion of children developed a middle ear complication type tympanic membrane perforation or cholesteatoma. Additional research remains necessary in order to detect risk factors of adverse middle ear outcome in this population.

## The refined STAMCO cholesteatoma classification in CWU surgery with bony obliteration technique

*H.F. van Waegeningh, J. van Dinther, A. Zarowski*

GZA Sint Augustinus, Antwerpen

### Objective

The objective of this study was to evaluate the predicting value of the refined STAMCO cholesteatoma classification system in surgical outcome and residual and recurrence rates of CWU surgery with obliteration of the mastoid and epitympanum.

### Study design

A retrospective cohort study was performed in a tertiary referral centre.

### Patients

Patients with acquired cholesteatoma treated with primary or revision CWU surgery with bony obliteration of the epitympanum and mastoid were identified retrospectively. A consecutive series of 64 ears in 62 patients operated from 2009-2014 by a single surgeon were evaluated.

### Intervention

Obliteration was performed with bone-chips in combination with bone pâté. Patients were followed up with micro-otoscopy and MRI with diffusion weighted imaging (DWI) at least 3 year postoperatively. In 60 cases reconstruction of the ossicular chain was performed using a remodelled autologous or allogeneic incus or malleus head.

### Main outcome measures

The following outcome measures were analyzed: Residual rate, recurrence rate, short-term hearing outcome within 2 months postoperatively and at long-term hearing outcome at least 4 months postoperatively. Effect of ossicular status on hearing outcome (*AHEP plot, AC status, AC gain, ABG closure*) was analyzed, as well effect of cholesteatoma affected sites on hearing outcome and risk of residual or recurrent disease.

### Results

Sixty-four ears in sixty-two patients were treated with CWU surgery combined with obliteration of the epitympanum and mastoid: 30 right (47%) and 34 left ears (53%), 29 male (45%) and 35 female (55%) ears. 44 ears (69%) were primary cholesteatoma cases. All these primary cases were extensive cholesteatomas, with 98% involvement of the tympanic cavity, 89% of the attic, 48% of the anterior epitympanic space, 50% of sinus tympani and 55% of the antrum and/or mastoid. The other 20 cases (31%) were revision surgery, with 85% involvement of the tympanic cavity, 80% of the attic, 40% of the anterior epitympanic space, 10% of the sinus tympani and 50% of the antrum and/or mastoid. The mean postoperative follow up was 42 months (SD 17.93). Mean follow-up until the last MRI-DWI was 36.52 months (SD 17.52). In 3% of all operated ears recurrence was present at last follow-up, in 0% residual cholesteatoma was present. Fifty-four cases with remodelled autologous or allogeneic incus or malleus head ossicular reconstruction underwent long term audiological follow-up. Long-term hearing results showed improvement on AC pure-tone thresholds in 24 ears (44%), no change in 23 ears (43%) and deterioration in 7 ears (13%). Ossicular chain status and cholesteatoma site involvement according to the STAMCO staging system did not show any significant effect on hearing outcome, neither did individual ossicular status.

### Conclusion

The predicting value of the refined STAMCO cholesteatoma classification system in surgical outcome of CWU surgery with obliteration of the mastoid and epitympanum seems limited. The predicting value of the refined STAMCO cholesteatoma classification on residual and recurrence rates remains to be evaluated in larger series.

## **Resting state EEG microstate in tinnitus patients reveals dynamic changes in attention and auditory cortical networks during residual inhibition**

*A. Deklerck, H. Keppler, K. Paul, S. Degeest, G. Pourtois, I. Dhooge*

Department of Otorhinolaryngology, Ghent University Hospital, Ghent, Belgium

### **Introduction and aim**

Frequently, tinnitus neuroimaging experiments make use of auditory evoked paradigms, not being able to distinguish neuronal correlates actually underlying tinnitus, from disrupted auditory processing or associated phenomena (hyperacusis) in tinnitus patients. ‘Residual inhibition’ (RI) could be applied in these paradigms as a method to transiently suppress tinnitus, without acoustic interference during data acquisition. This EEG study aims at exploring state dependent changes in neural processing, between a ‘tinnitus-suppressed’ status and a ‘tinnitus’ status, while keeping all other experimental factors comparable between these two conditions. This is done by using topographic analysis of the EEG data i.e. microstates.

### **Material and methods**

3 groups of 10 age-, gender-, hearing- and tinnitus duration-matched subjects (tinnitus patients with RI-positive and –negative response respectively, and controls without tinnitus) were included in this resting state EEG study. A masking white noise (WN) and a non-masking narrow band noise (NBN) were alternately presented, followed by resting state, in order to allow data acquisition during tinnitus suppression (RI after WN) or presence (after NBN).

### **Results**

As our pilot study showed a very good reliability for RI duration ( $ICC(3,4) = 0.871$ ), RI could be used in the EEG experiment. Preliminary EEG results obtained in 4 tinnitus patients with RI response confirm that two microstates showed reliable changes: during RI/tinnitus suppression, the microstate corresponding to auditory network was decreased, while the one corresponding to the attention network was increased, relative to the control condition after NBN presentation (without tinnitus suppression). These results are supplemented and compared with data from other RI responders and control patients respectively.

### **Conclusions**

Resting state EEG experiments using RI, could give insight into neuronal functional connectivity alterations in tinnitus patients without (external) acoustic interference. EEG data indicate that transient dynamic interaction between attention and auditory cortical networks could underlie tinnitus suppression.



# Retrospective and cross-sectional analysis of recipients of the Nucleus contour using a cochleostomy approach and the Nucleus CI422/522 using the round window approach

C. W. M. Snels<sup>1</sup>, W. Huinck<sup>2</sup>, E. Mylanus<sup>1</sup>, I. Dhooge<sup>1</sup>

<sup>1</sup>Department of Otorhinolaryngology, University Hospital Ghent, Belgium, <sup>2</sup>Department of Otorhinolaryngology, Radboud University Nijmegen, The Netherlands

## Introduction and aim

In cochlear implantation (CI) candidates with residual hearing, surgery will be aimed at the preservation of residual hearing (HP, hearing preservation). Different types of surgery and different electrode array designs exist for this purpose. The aim of this study is to gain insight in two HP methods: a cochleostomy approach using a Nucleus contour advance electrode and a round window approach using a Nucleus CI422/522 electrode.

## Material and methods

A retrospective and cross-sectional analysis of patients who received a Nucleus contour advance using the cochleostomy approach and patients who received a Nucleus CI422/522 using the round window approach in the Radboudumc Nijmegen and the University Hospital Ghent since 2010 was performed. Four HP definitions were defined. Definitions 1 and 2 use a pure-tone average (PTA) of 250, 500, and 1000 Hz. Definitions 3 and 4 use a PTA of 250, 500, 1000, and 2000 Hz. Definitions 1 and 3 differentiate from definition 2 and 4 by using different calculations for HP outcome.

## Results

Results can be found in table 1. In both groups the results show that HP was significantly affected by follow up time for all four HP definitions (p<0.05).

## Conclusion

Hearing preservation outcomes decline over time in patients who received a Nucleus contour advance electrode using a cochleostomy procedure and in patients who received a Nucleus CI422/522 electrode using a round window procedure.

Table 1.  
Results retrospective and cross-sectional analysis

	Cochleostomy and Nucleus contour advance electrode				P-value	Round window and Nucleus CI422/522 electrode				P-value
	Mean HP – Fitting CI	HP category – Fitting CI	Mean HP – 1 year postop	HP category – 1 year postop		Mean HP – Fitting CI	HP category – Fitting CI	Mean HP – 1 year postop	HP category – 1 year postop	
Definition 1 <sup>1</sup>	18.36	Partial	22.37	Unsuccessful	0.000	19.46	Partial	28.75	Unsuccessful	0.001
Definition 2 <sup>2</sup>	33.01	Partial	13.90	Minimal	0.015	57.66	Partial	36.40	Partial	0.000
Definition 3 <sup>3</sup>	15.45	Partial	19.04	Partial	0.000	16.08	Partial	24.63	Unsuccessful	0.001
Definition 4 <sup>4</sup>	30.60	Partial	11.89	Minimal	0.003	58.36	Partial	35.67	Partial	0.001

<sup>1</sup> Absolute difference postoperative – preoperative of an unaided pure-tone average (PTA) of 250, 500, and 1000 Hz. <sup>2</sup> A HP percentage calculated with the formula: HP (%) = [1-(PTA postoperative – PTA preoperative)/(120 – PTA preoperative)] \* 100. A PTA of 250, 500, and 1000 Hz is used. <sup>3</sup> Absolute difference postoperative – preoperative of an unaided PTA of 250, 500, 1000, and 2000 Hz. <sup>4</sup> A HP percentage calculated with the formula: HP (%) = [1-(PTA postoperative – PTA preoperative)/(120 – PTA preoperative)] \* 100. A PTA of 250, 500, 1000, and 2000 Hz is used.

## **Young Otolaryngologist – International Federation of Oto-rhino-laryngological Societies: Establishment, development and perspectives**

*J. R. Lechien<sup>1,2#</sup>, D. R. De Siat<sup>3#</sup>, V. Couloignier<sup>4</sup>, N. Teissier<sup>5</sup>, T. Ayad<sup>6\*</sup>, N. Fakhry<sup>7\*</sup>*

<sup>1</sup>Laboratory of Anatomy and Experimental Oncology, Faculty of Medicine, UMONS Research Institute for Health Sciences and Technology, University of Mons (UMons), Mons, Belgium, <sup>2</sup>Department of Otorhinolaryngology and Head and Neck Surgery, CHU de Bruxelles (CHU Saint-Pierre), Université Libre de Bruxelles, Bruxelles, Belgium, <sup>3</sup>Department of Otorhinolaryngology and Head and Neck Surgery, CHU Saint-Luc, Université Catholique de Louvain, Bruxelles, Belgium, <sup>4</sup>Department of Otorhinolaryngology and Head and Neck Surgery, Hôpital Necker Enfants Malades, Assistance Publique-Hôpitaux de Paris, Université Paris Descartes, Faculté de Médecine, Paris, France, <sup>5</sup>Department of Pediatric Otorhinolaryngology, Inserm U1141, DHU Protect, Hôpital Robert Debré, Paris, France, <sup>6</sup>Department of Otorhinolaryngology and Head and Neck Surgery, CHU de Montréal, Montréal, Canada, <sup>7</sup>Department of Otorhinolaryngology and Head and Neck Surgery, CHU La Conception, Marseille, France. # Co-first or \*senior authors

In the last World ENT Congress in Paris (June, 2017), the international board of International Federation of Oto-rhino-laryngological Societies (IFOS) decided to establish the Young Otolaryngologist IFOS regrouping otolaryngologists younger than 45 years old. The aim of this group is to develop exchanges, international networks and researches involving young otolaryngologists of the 5 continents. To realize these objectives, the YO IFOS board subdivided the group in 4 mains committees: Education, Research, Networking, and Congress organization committees. Moreover, the group is also structured in subgroups of exchanges according to the world region membership. Within a few months, all committees were operational. To date, among the research projects, the members want to develop international studies in head and neck oncology, otology, voice disorders, rare diseases (with a pooling of little cohorts to get a higher study cohort), and, recently, two projects interesting to the young resident training are being developed. The aim of this poster is to present the structure, development, and the perspectives related the establishment of the YO IFOS.

## **Endoscopic surgery for juvenile nasopharyngeal angiofibroma: experience of a tertiary center from 1993-2016**

*L. Poels, M. Jorissen*

Department of Otorhinolaryngology, Head and Neck Surgery, University Hospitals Leuven, Belgium

### **Introduction and aim**

Evaluation of the efficacy of endoscopic surgery for juvenile nasopharyngeal angiofibroma.

### **Material and methods**

Retrospective analysis of the medical records of 34 patients who underwent endoscopic sinus surgery for a juvenile nasopharyngeal angiofibroma in the University Hospitals of Leuven (Belgium).

### **Results**

All patients were male and mean age was 18.7 years. According to the classification of Radkowski one patient was stage IA, five stage IB, five stage IIA, thirteen stage IIB, four stage IIC, three stage IIIA and three stage IIIB. Pre-operative angiography with embolisation was performed in all patients except one. The patients were followed during a mean period of 33.6 months. Five patients (14.7%) showed recurrence after a mean period of 9.2 months. Two of them (one stage IIIA and one stage IIIB) had tumor progression of residual tumor tissue due to incomplete macroscopic tumor removal after 4 and 3 months respectively. They underwent a successful revision procedure. Three patients (one stage IIC, one stage IIIA and one stage IIB) had tumor recurrence after 6, 9 and 24 months respectively. Two of them were disease-free after revision endoscopic surgery. The other patient was treated conservatively and showed stable, asymptomatic disease. The mean duration of the surgery was 84 minutes. The mean duration of hospital stay was 4.3 days. Two patients (5.9%) had an internal maxillary artery bleeding postoperatively and one patient (2.9%) had a cavernous sinus bleeding without associated permanent morbidity or mortality.

### **Conclusions**

The results of this study demonstrate that endoscopic surgery for a juvenile nasopharyngeal angiofibroma is an effective and safe technique with good outcomes and low postoperative morbidity. This technique should be used as first choice for treatment of tumors upon stage IIB and is a worthy alternative to open procedures for tumors at stages IIC-IIIB when performed by an experienced surgeon.

## **Diced cartilage in fascia (DCF) in functional septorhinoplasty**

*L. Celis<sup>1,2</sup>, F. Declau<sup>1</sup>*

<sup>1</sup>Department of Otorhinolaryngology and Head & Neck Surgery, GZA ziekenhuizen, Antwerpen, Belgium, <sup>2</sup>Faculty of Medicine and Health Sciences, University of Antwerp, Campus Drie Eiken, Antwerp, Belgium

### **Introduction and aim**

Reconstruction of the nasal dorsum by diced costal cartilage grafts wrapped in fascia for dorsal augmentation has initially been described by Daniel and Calvert in 2004 and modified by Cerkes et al. in 2015. The objective of this study was to assess the aesthetic outcome after functional septorhinoplasty using diced cartilage in fascia (DCF) in the difficult nose.

### **Material and methods**

Eight consecutive patients who underwent a dorsal augmentation with DCF during the last two years were reviewed retrospectively. Data collected from patient charts, surgical records, patient photos and Utrecht Questionnaire were analysed. The subjective assessment of aesthetic surgical outcome was rated using a patient recorded VAS –scale, indicating the degree of satisfaction in aesthetic appearance of the nose (0= dissatisfied, 10 = maximum satisfied).

### **Results**

All 8 patients presented with a low-profile or saddle nose due to trauma, previous surgery or cocaine abuse. The male-to-female ratio was 1:3; median age was 40,5 years (range, 16-52). Dorsal reconstruction was performed in each case with spreader and septal extension grafts from costal cartilage. Diced rib cartilage wrapped in temporal fascia (n=1) or rectus abdominis fascia (n=7) was used for aesthetic reconstruction of the dorsum. All surgeries were performed by the senior author, using an external approach. Tip surgery was combined in all cases. Mean follow up period was 11,5 months (range, 3-20 month). The median VAS-score preoperatively was 2,5. All patients exhibited a good subjective aesthetic result, represented by a median increase in VAS score of 5. Mean postoperative VAS score was 7,5 registered on the latest date of follow-up. Mild complications were observed in 2 patients: mild tip retraction was seen during follow-up. No DCF-graft resorption was documented up to a maximal follow-up of 20 months.

### **Conclusion**

DCF is a useful and effective technique for dorsal augmentation in more advanced rhinoplasties. Our experience demonstrated a significant satisfaction in aesthetic appearance of the nose postoperatively, measured as difference in VAS-score preoperative versus postoperative.

## **Unusual presentations of diffuse large B cell lymphoma: case series**

*F. Rosenzweig, K. Trimmel, C. De Dorlodot, Ph. Eloy*

HNS & ENT Department, CHU UCL Namur, Site de Godinne, Yvoir

DLBCL is an aggressive, fast-growing lymphoma. It represents the most common form of non-Hodgkin lymphoma (NHL), accounting for approximately 25% of NHL in North America and Western Europe. NHL is an uncommon tumor of the paranasal sinuses and ocular adnexal region in adults, representing no more than 5.8 to 8 percent of the entire malignant neoplasia in these localizations.

### **Clinical case 1**

A 40 year-old man presented to the outpatient clinic with a lump of the forehead and a past medical history of “rhinosinusitis”. The clinical examination revealed a soft tissue mass, developed medially on his forehead. A sinus CT scan showed an opacification of the medial part of the frontal sinus with a swelling of the forehead. A medical treatment was initiated consisting of systemic broad spectrum antibiotics and systemic steroids as there was a suspicion of Pott’s puffy tumor. The patient responded well to the therapy but the swelling relapsed at the completion of the treatment.

Multiple biopsies and samples for bacteriological examination were then performed under general anesthesia during a therapeutic window. No pus was found. The histopathological examination confirmed the diagnosis of a diffuse large B cell lymphoma. The patient was treated successfully in the haematologic department with chemotherapy.

### **Clinical case 2**

A 85 year old man presented to the outpatient clinic with an history of unilateral epiphora. He noticed a swelling in the medial canthal region. The clinical examination (syrringing) was consistent with an obstruction of the lacrimal pathway. A sinus CT scan demonstrated an expanding process in the maxillary sinus with erosion of the anterior wall. MRI confirmed the tumoral aspect of the process. A medial endoscopic maxillectomy was performed to get histological samples. The definitive diagnosis was a DLBCL. The patient refused chemotherapy. He was then treated successfully with radiotherapy. Actually we are at 3 years follow-up.

### **Clinical case 3**

A 66 year old man was referred to the ENT consultation for epiphora and lump in the right cantus region. In his medical history we noticed arterial hypertension, chronic anemia due to a myeloproliferative syndrome, renal failure and CML. The clinical examination confirmed a swelling in the right canthal region. The syrringing demonstrated a stenosis of the lacrymal excretory system. A sinus CT scan excluded any sinus disease. It showed an expanding process adjacent to the lacrymal pathway. The MRI confirmed the tumoral aspect of the lesion. A FNB was done. The final diagnosis was a DLBCL. The patient responded well to radiotherapy.

### **Conclusion**

These 3 cases illustrated perfectly well the heterogeneity of the clinical presentation of the DLBCL in the “sinonasal region”. The clinician must think about it in all cases unresponsive to conventional management. Complete assessment is therefore mandatory. This is the only way to make the diagnosis as early as possible in order to give to the patient the optimal treatment with the best outcome.

## ***Lactobacillus casei* AMB-R2 restores nasal epithelial barrier integrity in chronic rhinosinusitis**

*K. Martens<sup>1</sup>, B. Steelant<sup>1</sup>, I. De Boeck<sup>2</sup>, B. Pugin<sup>1</sup>, S. F. Seys<sup>1</sup>, S. Lebeer<sup>2</sup>, P. W. Hellings<sup>1,3</sup>*

<sup>1</sup>Laboratory of Clinical Immunology, Catholic University Leuven, Leuven, Belgium, <sup>2</sup>Research Group Environmental Ecology and Applied Microbiology, University of Antwerp, Antwerp, Belgium, <sup>3</sup>Department of Otorhinolaryngology, University Hospital Leuven, Leuven, Belgium

### **Introduction and aims**

Epithelial barrier dysfunction is demonstrated in patients with chronic rhinosinusitis with nasal polyps (CRSwNP). Lactobacilli are thought to restore epithelial barrier dysfunction, though its effect on barrier function in CRSwNP has not been studied. We here evaluated the barrier restoring capacity of *Lactobacillus casei* AMB-R2 in CRSwNP.

### **Material and methods**

Sinus and/or nasal polyp tissue from patients with CRSsNP (n = 9) and CRSwNP (n = 24) were collected during functional endoscopic sinus surgery. The inferior turbinate from non-allergic patients were used as control (n = 12). The collected tissue was mounted in Ussing chambers and epithelial integrity was evaluated by measuring trans-tissue resistance (TTR) and paracellular flux of FITC-dextran 4 kDa (FD4). Nasal epithelial cells (NECs) from controls (n = 5) and CRSwNP patients (n = 5) were isolated and grown in air-liquid interphase. NECs were stimulated with *L. casei* AMB-R2 and epithelial integrity was evaluated by measuring trans-epithelial resistance (TER). BALBc mice (n = 5/group) were endonasally pretreated with *L. casei* AMB-R2 prior to 3 consecutive applications of *Staphylococcus aureus* enterotoxin B (SEB) to induce barrier dysfunction. One hour later, FD4 was applied to evaluate mucosal permeability.

### **Results**

TTR of sinus tissue and nasal polyps from CRSwNP patients was significantly decreased ( $p < 0.0001$ ) compared to controls and CRSsNP, associated with an increased FD4 passage ( $p < 0.0001$ ) in CRSwNP patients. Stimulation with *L. casei* AMB-R2 significantly increased TER in CRSwNP cultures to the level of controls, and had no effect in control. *In vivo*, mucosal permeability was decreased in mice treated with *L. casei* AMB-R2 (Mean  $\pm$  SEM:  $2.05 \pm 0.34$ ) compared to positive control (Mean  $\pm$  SEM:  $3.54 \pm 0.74$ ).

### **Conclusions**

The sino-nasal epithelial barrier is disrupted in CRSwNP compared to controls and patients with CRSsNP. Treatment with *L. casei* AMB-R2 restores nasal epithelial barrier integrity in CRSwNP *in vitro* and *in vivo*. Further research is needed to unravel the beneficial effect of *L. casei* AMB-R2 on barrier function.

## **The reasons of uncontrolled chronic rhinosinusitis and allergic rhinitis – a multicentre study**

*P. Van Bulck, L. Cools, S. Seys, M. S. Soumya, D. Nyembu, L. Zhang, E. Toskala, P. W. Hellings*

Department of Otorhinolaryngology, Head and Neck surgery University Hospitals Leuven, Belgium

### **Background**

Recent data show uncontrolled disease in 35% of patients with allergic rhinitis on medical treatment, and up to 40% of chronic rhinosinusitis patients after functional endoscopic sinus surgery (FESS). The reasons for uncontrolled disease can arbitrarily be divided into disease-related, diagnosis-related, treatment-related and patient-related factors. However, the relative importance of these factors in uncontrolled disease remains speculative. Insight into the factors responsible for uncontrolled disease is mandatory to define strategies for improving health care outcome in AR and CRS.

### **Aims**

This explorative study aimed to determine the factors causing uncontrolled AR and CRS and identifying the most common reasons for uncontrolled disease in uncontrolled AR and uncontrolled CRS.

### **Methods**

Patients with uncontrolled AR and CRS were asked to fill out a questionnaire and underwent a clinical examination at the outpatient clinic. Two independent physicians evaluated the one or multiple reasons for uncontrolled disease. The study was performed in the University Hospital of Leuven for CRS. For AR the study was performed in different centers world wide: University Hospital of Leuven (Belgium), Capital Medical University of Beijing (China), University Hospital of Kinshasa (Congo), Indian Academy of Allergy (Bangalore, India) and Temple University of Philadelphia (United States of America).

### **Results**

In uncontrolled AR patients ( $n = 430$ ), 76,7% of patients showed 2 or more reasons for uncontrolled disease. Disease related-factor (62%), also known as Severe Chronic Upper Airway Disease, was considered most often as the reason for uncontrolled disease. In 7% of patients it was the only reason of their uncontrolled disease. Followed by treatment (55,8%), patient (54%) and diagnosis (46,8%) related factors. In uncontrolled CRS patients ( $n = 200$ ), 66,0% of patients showed 2 or more reasons for uncontrolled disease. Disease related factor (70%) was considered most often as the reason for uncontrolled disease, followed by treatment (48%), patient (44%) and diagnosis (32%) related factors.

### **Conclusion**

This observational study sheds new light on uncontrolled AR and CRS, with disease related factors being most frequently associated with uncontrolled disease. A better understanding of uncontrolled disease will guide us in defining optimal care pathways in AR and CRS.



## **Endoscopic Septoplasty: Literature review, surgical techniques and retrospective analysis at the University Hospitals Leuven**

*S. Vandebroeck, M. Jorissen*

Department of Otorhinolaryngology, Head and Neck Surgery, University Hospitals Leuven, Belgium

### **Introduction and aim**

Endoscopic septoplasty is a relatively new approach to the deviated nasal septum. Since its introduction in 1991, numerous techniques have been developed, each with its own advantages and limitations. A literature review is presented, along with the outcomes of endoscopic spur resection at the University Hospitals Leuven.

### **Materials and methods**

Research of literature listed in Medline and Google Scholar databases. Review of records of all patients undergoing endoscopic spur resection at the University Hospitals Leuven between 2001 and 2015.

### **Results**

The search yielded 393 articles, of which 34 were considered relevant and discussed below. Two hundred and five patients were identified undergoing endoscopic spur resection, of which 36 were excluded. Procedure time was five minutes on average and access was achieved in all patients. Complete resolution of nasal airway obstruction was seen in 74.75%, an additional 20.20% experienced a marked improvement. Complications were minor: epistaxis (2.37%), asymptomatic adhesions (1.78%), septal hematoma (0.59%), transient dental hyperesthesia (0.59%) and asymptomatic septal perforation (0.59%).

### **Conclusions**

Endoscopic septoplasty offers improved visualisation and the possibility of limited flap dissection, particularly helpful when dealing with isolated spurs, posterior deviations and revision septoplasty. It can also be used as an effective teaching tool and offers an improved surgical transition to endoscopic sinus surgery. Reported success and complication rates are comparable to those seen in traditional approaches. Multiple techniques exist, each with its own advantages. Endoscopic spur resection as done at the University Hospitals Leuven is a quick, safe and efficient technique when dealing with isolated septal spurs, especially when combined with endoscopic sinus surgery.

## **A rare cause of recurrent epistaxis: the epithelioid angiomatous nodule of the nasal cavity**

*C. Van Zuylen, P. Brihaye, A-L. Mansbach*

University Children's Hospital Reine Fabiola, Free University of Brussels (ULB), Brussels, Belgium

### **Introduction and aim**

Epistaxis is a frequent cause of consultation in Pediatric Otorhinolaryngology. In 90% of the cases, the origin of the bleeding is localized at the Kiesselbach's plexus. We report the case of an 11-year-old girl presenting a rare lesion, causing recurrent epistaxis. The aim of this presentation is to underline the importance of a precise and complete assessment in case of recurrent nosebleed in children.

### **Case report**

An 11-year-old girl presented a recurrent bilateral epistaxis following an infectious episode. Bleeding decreased after 2 chemical cauterizations, but never stopped completely. The blood test, only accepted by the parents after 1 month of evolution, showed an Hemoglobin level at 4.7 g/dl. Nasal endoscopy showed a bluish pediculed nodule localized at the posterior part of the middle turbinate with a weak but active bleeding. The imaging assessment showed an aspecific circumscribed lesion of 5.5 mm localized at the root of the middle turbinate. A complete transnasal endoscopic resection was performed, which resolved the bleeding. At histology, an epithelioid angiomatous nodule was diagnosed.

### **Discussion**

The nasal epithelioid angiomatous nodule is a benign vascular lesion, first described in 2004 on cutaneous tissue, with rare localization in the nasal cavity. Only 5 cases have been previously reported. There is no recurrence after complete excision.

We propose an algorithm based on a precise history to guide the clinician in the decision to perform a thorough assessment based on a nasal endoscopy, a blood test and an imaging evaluation, in case of epistaxis in a child.

### **Conclusion**

We report the case of an epithelioid angiomatous nodule, which caused a recurrent nasal epistaxis with a severe anemia. We underline the importance of a precise history in case of recurrent epistaxis in children.

## **The incidence of complications after extra-capsular tonsillectomy in one-day surgery stage: A retrospective study of 2714 cases**

*A. Noel, Q. Mat, C. Napoli, M. Barthelemy, S. Tainmont, D. Lejeune, P. Simon, R. Mehta, C. d'Adesky, J-P Duterme*

Hôpital Civil Marie Curie /C.H.U. de Charleroi, Belgium

### **Introduction and aim**

Tonsillectomy is probably the most frequent surgical procedure used in E.N.T. Post-tonsillectomy hemorrhage remains the most serious complication of tonsillectomy. Other complications following this surgical intervention are odynophagia (pain and feeding difficulties) and respiratory failure. The aim of this large retrospective study, including more than 2500 cases, is to assess, the frequency of these different surgical complications secondary to extra-capsular tonsillectomy.

### **Material and methods**

It is a retrospective study on a cohort of 2714 patients who underwent a tonsillectomy with or without adenoidectomy in one- day surgery stage, between 2007 and 2016. All the patients received a medical management for pain complaints. Postoperative oversight in the first 6 hours was performed. In addition, a secondary follow-up within the week following the surgery has also been carried out. The incidence of complications who needed a hospitalisation is analyzed. Hemorrhage occurrence is divided into two broad categories; primary, occurring <24 hours after surgery and secondary, occurring >24 hours .

### **Results**

144 of the 2714 (5.3%) patients had complications. The most frequent was hemorrhage occurring in 114 (4.3%) of them. 6 patients (0.22%) had primary hemorrhage resulting in a prolonged hospitalisation. 49 patients (1.8%) with a secondary hemorrhage had a secondary hospitalisation. A surgical re-intervention has been necessary in 23 (0.84%) of them. From a statistical point of view, the hemorrhage was more frequented both in patients  $\geq 16$  years old ( $p < 0.001$ ) or with O blood group ( $p < 0.001$ ). 23 patients (0.84%) had severe odynophagia with hospitalisation. No respiratory failure was found.

### **Conclusions**

Extra-capsular tonsillectomy is a very safe procedure who could easily be done in a one-day surgery stage. In case of complication postoperative hemorrhage is the most frequent secondary complication; nevertheless surgical re-intervention is rare.

## **Contribution of Montgomery® Implant System in medialization thyroplasty: postoperative voice results**

*G. Delahaut, A. Rybowski, V. Bachy, G. Lawson, M. Remacle, S. Van der Vorst*

ENT department, CHU UCL Namur site Godinne

### **Introduction and aim**

Medialization thyroplasty is a standard procedure in the treatment of persistent glottal gaps in patients with unilateral vocal fold paralysis (UVFP). In our institution, Montgomery® Implant System have been used since 2009 to manage glottic closure defect following UVFP, endoscopic cordectomies and presbyphonia. The aim of this retrospective study is to evaluate the vocal results in patients who underwent this surgical technique. Our secondary objective is to compare results between gender subgroups.

### **Material and methods®**

Sixty eight patients who underwent thyroplasty using the Montgomery® Implant System in our institution, between June 2009 and December 2017, were originally selected. Only patients with UVFP were included and patients with missing data were excluded. This cohort corresponds to 30 patients, 16 males and 14 females. Twenty subjects among those presented with a left UVFP and 10 with a right impairment.

Vocal assessment included perceptual scale (GRABSI), aerodynamic measurements (estimated subglottic pressure, maximum phonation time, phonatory quotient), acoustic information (fundamental frequency, frequency and intensity range, jitter and dysphonia severity index) and self-assessment (dysphonia handicap index).

Statistical analyses were performed on each parameter separately using univariate and multivariate models.

### **Results**

Clinicians' perceptual evaluations indicated an improvement in voice quality for most patients. Moreover, most of the patients expressed satisfaction with this surgical procedure and resulting voice quality.

Nearly each parameter of the vocal assessment improved significantly after surgery. Absolute median maximum phonatory time showed an increase of 4.10 sec ( $p < 0.05$ ), whereas VHI score decreased of 36 points ( $p < 0.05$ ). Gender comparison revealed a trend to better improvement in men than in women, but without reaching significance.

### **Conclusions**

This retrospective study confirms the excellent vocal results after medialization thyroplasty using Montgomery® Implant System. Further studies with prospective datas are needed to evaluate the results according to the patient gender.

## **The utility of suprascapular artery island flap in head and neck reconstruction surgery after cervico-facial oncological resection**

*R. Cheikh Youssef, D. Dequanter, A. Rodriguez Ruis, G. Chantrain, R. Javadian*

Oto-rhino-laryngology, Head and Neck surgery department, Saint-Pierre University Hospital, ULB, Brussels, Belgium

### **Introduction**

Reconstruction of defects after oncologic resection of head and neck tumors is challenging and complex.

The goal of this retrospective study is to evaluate the supraclavicular artery island flap and its utility in head and neck reconstruction, especially when reconstruction require traditional free flaps to repair surgical wounds but are not recommended.

### **Methods**

We reviewed our two years experience in the use of the supraclavicular artery island flap (SCAIF) in 10 cases as an alternative to free flaps in closing defects after resection of head and neck tumors. In 5 cases, the pedicled supraclavicular artery island flap was used as revision surgery after free flap failure.

The indications for the flap use were defects due to resection of stage II-IV cancer in the head and neck region. The site, the total operative time, complications and functional outcomes were assessed.

### **Results**

We identified 15 patients with a total of 16 SCAIFs. One patient received bilateral SCAIFs. Of the patients, 10 were men and 5 were women. Head and neck oncologic patients underwent tumor resection followed by immediate reconstruction using a supraclavicular artery island flap.

10/15 of the patients received previous radiotherapy to the head and neck region. All the patients had undergone multiple surgical procedures. Mean flap dimensions were 6.0 cm (range, 5-7 cm) wide and 22.0 cm (range, 14-26 cm) long. The proximal part of the flap was deepithelialized to match the defect, resulting in a mean skin paddle length of 8.0 cm (range, 5-12 cm).

After a mean follow-up was 13 months (range, 3- 20 months), the flap survival was 100%. However, 2 patients had partial loss of the flap. All flaps were harvested in less than one hour. The donor sites were closed primarily and did not require additional surgery. No donor site wound dehiscence was reported. No infection or cellulitis were observed. None of the patients reported functional donor-site morbidity.

### **Conclusions**

The supraclavicular island flap provides a safe option for head and neck reconstruction of oncologic defects when free flaps are not recommended. Moreover, the supraclavicular flap represented an opportunity in reconstruction after free flap failure with a low complications rate and morbidity at both the recipient and donor sites.

## **Transoral robotic surgery (TORS) hypopharyngectomy: feasibility and outcomes**

*Sa. Hassid, S. Van der Vorst, £G. Delahaut, V. Bachy, O. Desgain, G. Lawson*

ENT department, CHU UCL Namur - site Godinne, Belgium

### **Introduction and aim**

With the development of the minimal invasive surgery, transoral robotic procedures are expanding for head and neck tumors. Most reviews describe oropharynx and laryngeal (supraglottic) localization. We report the feasibility and outcomes of patients who underwent primary TORS hypopharyngectomy.

### **Material and method**

Between September 2009 and July 2017, 22 patients with hypopharyngeal squamous cell carcinoma (piriform sinus or posterior pharyngeal wall) underwent TORS hypopharyngectomy with curative intent, utilizing da Vinci robotic system. We report a retrospectively data analysis.

### **Results**

From 22 successful hypopharyngectomy, no conversion to open procedure was needed. There was no mortality during per-operative or immediate post-operative period. Three patients (13%) presented a post-operative bleeding; among those, two were managed by surgical revision. No fistula (0%) was encountered. Three patients (13%) received a transient tracheotomy (< 2 months); two for respiratory distress and one for post-operative bleeding. One patient had positive margins confirmed on final pathology. With a mean follow-up time of 37,2 months, recurrence developed in 6 patients (27%), 10 patients were alive without recurrence (46%) and 6 patients died without evidence of recurrence (27%). Concerning functional outcomes, patients started oral feeding after an average of 7 days (range 1-30) with a return to full oral diet at an average of 10 days (range 1-35). Naso-gastric feeding tubes were removed after a median period of 16 days [CI: 1-183]. Two patients (9%) needed gastrostomy, one for less than 1 month and the other for one year. Length of hospitalization ranged from 3 to 61 days (mean: 17 days; median: 13 days).

### **Conclusion**

Transoral robotic hypopharyngectomy is a safe and feasible technique. Patients' outcomes are favorable and the post-operative morbidity is reduced compared to open neck approach. Hospitalization length is reduced and patients required a short period for safe swallowing.

## **Transoral robotic total laryngectomy (TORS-TL): the experience of CHU UCL Namur**

*G. Delahaut, G. Gersdorff, S. Van der Vorst, V. Bachy, O. Desgain, G. Lawson*

ENT department, CHU UCL Namur site Godinne

### **Introduction and aim**

Total laryngectomy is a standard primary surgical procedure for extended laryngeal cancer or a salvage surgical treatment for persistent and recurrent laryngeal disease after (chemo)-radiation. It is also a surgical option to cure non-functional larynx after radiation therapy. Postoperative complications such as pharyngocutaneous fistulae and tissue necrosis are common in those conditions. Transoral robotic surgery (TORS) has demonstrated excellent oncological and functional outcomes in oropharynx and supraglottic cancers. The aim of our study is to demonstrate the feasibility and the safety of transoral robotic total laryngectomy (TORS-TL), and to analyze oncological outcomes, complications rate and hospitalization length.

### **Material and methods**

Forty-one patients were prospectively included in this single tertiary university center study, conducted from August 2011 to December 2017. Thirty-one patients underwent TORS-TL for oncological purposes and 10 for functional reason. We report data analysis for surgical feasibility, perioperative adverse events, surgery duration, oncological outcomes, postoperative complications, length of hospitalization, time to voice prosthesis insertion and feeding tube dependency.

### **Results and discussion**

All patients received transoral procedure. No conversion was needed. Our preliminary results demonstrate that TORS-TL is a safe and feasible procedure with less complication rate compare to conventional open procedures. As patient selection is correctly assessed, it is also a safe oncological procedure as confirmed by the low rate of positive margins on final pathology assessment. Our initial functional outcomes for TORS-TL are encouraging and prospective multicenter studies are encouraged.

### **Conclusions**

TORS-TL is a feasible and safe surgical procedure with limited dissection of cervical spaces and harvesting the maximum amount of healthy pharyngeal mucosa for closure. Our preliminary results confirm excellent oncological outcomes and a complication rate similar to conventional open procedures.



## Voice quality and orofacial strength in patients with early idiopathic Parkinson disease: a controlled study

J. R. Lechien<sup>1,3</sup>, S. Blecic<sup>5</sup>, K. Huet<sup>2</sup>, A. Rodriguez<sup>4</sup>, B. Harmegnies<sup>2#</sup>, S. Saussez<sup>1,3#</sup>

<sup>1</sup>Laboratory of Anatomy and Cell Biology, Faculty of Medicine, UMONS Research Institute for Health Sciences and Technology, University of Mons (UMons), Mons, Belgium, <sup>2</sup>Laboratory of Phonetics, Faculty of Psychology, Research Institute for Language sciences and Technology, University of Mons (UMons), Mons, Belgium, <sup>3</sup>Department of Otorhinolaryngology and Head and Neck Surgery, RHMS Baudour, EpiCURA Hospital, Baudour, Belgium, <sup>4</sup>Department of Otorhinolaryngology and Head and Neck Surgery, CHU Saint-Pierre, Brussels, Belgium, <sup>5</sup>Department of Neurology, EpiCURA Hospital, Baudour, Belgium. #Contributed equally to this work and should be regarded as *joint last authors*

### Introduction

Ninety percent of patients with idiopathic Parkinson's disease (IPD) developed early dysphonia, and subtle speech impairment, which is usually related to orofacial muscular dysfunctions. The aim of this study is to assess the usefulness of voice and speech qualities as outcome of Levodopa challenge test used for the IPD diagnosis.

### Material and methods

20 patients with early IPD and 10 healthy subjects were recruited and evaluated for clinical findings (Hoehn & Yahr scale), voice handicap index, maximal phonation time, phonatory quotient, percent jitter, percent shimmer, noise-to-harmonic ratio, and orofacial muscular strength (Iowa Oral Performance Instrument) at baseline, throughout the Levodopa challenge test, and after therapeutic stabilization.

### Results

The intake of a standardized dose of L-Dopa (levodopa challenge test) significantly improved aerodynamic (phonatory quotient) and acoustic (percent jitter) measurements depending on the subglottic airflow. We did not found similar improvement after medical stabilization of patients despite an improvement of Hoen & Yahr mean score. The intake of levodopa significantly improved cheeks and lips strength involved in speech quality during the challenge test and after the therapeutic stabilization. We did not found substantial improvement in all evaluations in healthy subjects.

### Conclusions

These findings support a differential impact of levodopa on voice and speech functions in early diagnosed IPD and a mismatch between the clinical, speech, and voice quality improvements once the patient is medically stabilized. Voice and orofacial muscular strength can be used as outcomes of levodopa efficiency in IPD.

**Keywords:** Parkinson; Voice; Speech; IOPI; acoustic.

## Voice quality outcomes of idiopathic Parkinson disease medical treatment: a systematic review

J. R. Lechien<sup>1,3</sup>, S. Blecic<sup>4</sup>, K. Huet<sup>2</sup>, V. Delvaux<sup>2</sup>, M. Piccaluga<sup>2</sup>, A. Rodriguez<sup>3</sup>, B. Harmegnies<sup>2#</sup>, S. Saussez<sup>1,3#</sup>

<sup>1</sup>Laboratory of Anatomy and Cell Biology, Faculty of Medicine, UMONS Research Institute for Health Sciences and Technology, University of Mons (UMons), Mons, Belgium, <sup>2</sup>Laboratory of Phonetics, Faculty of Psychology, Research Institute for Language sciences and Technology, University of Mons (UMons), Mons, Belgium, <sup>3</sup>Department of Otorhinolaryngology and Head and Neck Surgery, CHU Saint-Pierre, Brussels, Belgium, <sup>4</sup>Department of Neurology, EpiCURA Hospital, Baudour, Belgium. # Contributed equally to this work and should be regarded as *joint last authors*

### Introduction

To investigate voice quality (VQ) impairments in idiopathic Parkinson's disease (IPD) and to explore the impact of medical treatments on voice.

### Methods

Relevant studies published between January 1980 and June 2017 describing VQ evaluations in IPD were retrieved using PubMed, Scopus, Biological Abstracts, BioMed Central, and Cochrane databases. Issues of clinical relevance, including IPD treatment efficiency and voice quality outcomes, were evaluated for each study. The grade of recommendation for each publication was determined according to the Oxford Centre for Evidence-Based Medicine evidence levels.

### Results

The database research yielded 106 relevant publications, of which 33 studies met the inclusion criteria, for a total of 964 IPD patients. Data were extracted by 2 independent physicians who identified 21, 11, and 1 trials with IIIb, IIb, and IIa evidence levels, respectively. The main VQ assessment tools used were acoustic testing (N = 27), aerodynamic testing (N=10), subjective measurements (N = 8), and videolaryngostroboscopy (N = 3). The majority of trials (N = 32/33) identified subjective or objective VQ improvements after medical treatment (N = 10) or better VQ evaluations in healthy subjects compared to patients with IPD (N = 22). The methodology used to assess subjective and objective VQ substantially varied from one study to another. All of the included studies took into consideration the patient's clinical profile in the VQ analysis.

### Conclusion

The majority of studies supported that VQ assessments remain useful as outcome measures of the effectiveness of medical treatment. Further studies using standardized and transparent methodology for measuring acoustic parameters are necessary to confirm the place of each tool in IPD evaluation.

### Level of evidence

2a.

### Keywords

Parkinson; Voice; Speech; Acoustic; L-Dopa; Progression.

## **Gastric pull-up anastomotic failure and reconstruction with bipaddled ALT flap in total pharyngolaryngoesophagectomy: a case report and review of the literature**

*A. Lambert<sup>1,4</sup>, K. Van Landuyt<sup>2</sup>, M. Kint<sup>3</sup>, T. Cammaert<sup>1</sup>, S. Delrue<sup>1</sup>, G. De Vos<sup>1</sup>, Ph. Heylbroeck<sup>1</sup>, P. Neyt<sup>1</sup>, P. Van Der Eecken<sup>1</sup>, C. Vanclooster<sup>1,4</sup>*

<sup>1</sup>Department of Otorhinolaryngology - Head and Neck Surgery, General Hospital Sint-Lucas Ghent, <sup>2</sup>Department of plastic and reconstructive surgery, General Hospital Sint-Lucas and University Hospital Ghent, <sup>3</sup>Department of General and abdominal surgery, General Hospital Sint-Lucas Gent, <sup>4</sup>Department of Otorhinolaryngology, Head and Neck Surgery, University Hospital of Leuven

### **Introduction and aim**

Gastric pull-up is the preferred reconstructive option after total pharyngolaryngoesophagectomy for advanced carcinoma of the hypopharynx with extension to the cervical oesophagus. Fistulas due to gastric necrosis are a challenging and potentially fatal complication in the early postoperative period. However, guidelines in surgical management are lacking. We present a challenging case followed by a literature review on the management of gastric pull up anastomotic failures.

### **Case report**

We present a complicated case of squamous cell carcinoma of the hypopharynx and proximal oesophagus (pT4aN1M0) in a 69-years old female patient with a history of irradiation therapy for laryngeal cancer, and a bilateral mastectomy for ductal carcinoma with breast implant reconstruction. Primary surgical resection with curative intent was achieved by total pharyngolaryngoesophagectomy with gastric pull-up reconstruction. Radiological swallowing evaluation at 10 days postoperatively showed no signs of anastomotic leakage. A late paratracheostomal fistula was first identified at 20 days postoperatively, in addition to pars membranacea necrosis. A surgical exploration and plan were discussed, in agreement with the plastic and reconstructive surgeon, to harvest a free anterior lateral thigh (ALT) flap as an onlay graft to close the fistula. Peroperatively a complete necrosis and failure of the gastric anastomosis was identified over a length of approximately three centimetres, resulting in a paratracheostomal fistula to the superior right of the tracheostoma. Debridement of the necrotic mucosa resulted in a defect of approximately four centimetres. A bipaddled ALT free flap was harvested, tubulating the largest portion as an interposition graft between the gastric mucosa and the oropharynx. The remaining skin paddle was deepithelialised and used to cover the reconstruction site and the pars membranacea. We report a good postoperative healing and functional outcome.

## **Sudden airway obstruction caused by an infected laryngeal oncocytic cystadenoma masquerading as laryngopyocele**

*L. Celis<sup>1,2</sup>, K. Berghmans<sup>1</sup>, F. Declau<sup>1</sup>*

<sup>1</sup>Department of Otorhinolaryngology and Head & Neck Surgery, GZA ziekenhuizen, Antwerpen, Belgium, <sup>2</sup>Faculty of Medicine and Health Sciences, University of Antwerp, Campus Drie Eiken, Antwerp, Belgium

### **Introduction and aim**

We would like to report a case of sudden airway obstruction due to an infected oncocytic cystadenoma with extralaryngeal extension that was initially diagnosed as an infected combined laryngopyocele.

### **Case report**

We present a 66 year- old female smoker who was referred to the emergency department because of stridor, odynophagia and dysphagia with a progressive painful mass in the neck. Fiberendoscopy showed a polypoid mass originating from the left ventricle causing subtotal obstruction of the upper airway. CT showed a cystic mass with both an intralaryngeal as extralaryngeal component. It was diagnosed as a laryngopyocele and intravenous antibiotics were started for 1 week. The airway was secured by emergency intubation. The intralaryngeal component was endoscopically resected by marsupialization. Because of persistent airway obstruction after decompression due to supraglottic edema, the patient underwent a temporary tracheotomy. Histological examination revealed a oncocytic cystadenoma. In a second stage, the remaining cyst was completely resected both externally through a lateral neck incision as internally with transoral laser microsurgery.

### **Discussion**

A laryngocele is an abnormal dilation of the laryngeal saccule that extends upward within the false vocal fold, is filled with air, and is in communication with the laryngeal lumen. Laryngoceles are categorized as internal or combined. If the laryngocele becomes obstructed, the mucus produced by the mucous glands can accumulate, leading to a laryngomucocele. When it is infected, a laryngopyocele forms. Laryngeal oncocytic cystadenomas are a special type of laryngeal cysts that are lined by oncocytes. Oncocytes are hypertrophic epithelial cells with excessive mitochondria that have a distinctive eosinophilic cytoplasm. Oncocytic metaplasia of the epithelial respiratory cells lining the larynx is very common and represent rather a degenerative change in a more advanced age. They are usually located endolaryngeally. However, the present case represents a combined laryngeal cyst and poses a more diagnostic and therapeutic challenge requiring not only endoscopic excision but also an open procedure.

### **Conclusion**

To our knowledge an extralaryngeal extension of a laryngeal oncocytic cystadenoma is extremely rare. Because of the similar clinical features a differential diagnosis with a laryngopyocele or -mucocele should be made by histological examination.

## **Huntington's disease in a patient presenting at the vertigo clinic**

*R. Van Geet<sup>1</sup>, J. Claes<sup>1</sup>, A. Boogers<sup>3</sup>, D. Crosiers<sup>3</sup>, V. Van Rompaey<sup>1,2</sup>*

<sup>1</sup>Dept. Otorhinolaryngology & Head and Neck Surgery, Antwerp University Hospital, Belgium, <sup>2</sup>Faculty of Medicine and Health Sciences, University of Antwerp, Belgium, <sup>3</sup>Dept. Neurology, Antwerp University Hospital, Belgium.

### **Introduction and aim**

Huntington's disease is an autosomal dominant neurodegenerative disorder caused by an expansion of the cytosine-adenine-guanine trinucleotide repeats in the Huntingtin gene. It is characterized by progressive motor disability (including chorea), mental disturbances (including cognitive decline, changes in personality, and/or depression) and a family history consistent with autosomal dominant inheritance. The mean age of onset is 35 to 44 years and median survival is 15 to 18 years. We report the case of a patient that presented to the ENT department with symptoms of instability and vertigo, where eventually Huntington's disease was identified.

### **Case report**

An 82-year-old woman presented at the outpatient clinic with positional short-lasting vertigo spells and gait instability since 2 years. She did not report hearing loss or tinnitus, or other otologic symptoms, audiometry was normal. MRI of the cerebellopontine angle was performed 2 years ago and was normal. She had a history of mammary carcinoma. On video-oculography, no spontaneous or gaze-evoked nystagmus could be observed. During Dix-Hallpike maneuver to the left side a torsional clockwise nystagmus was observed. Initially, a left-sided posterior canal benign paroxysmal positional vertigo (BPPV) was considered as the putative diagnosis for the vertigo spells and an Epley manoeuvre was performed. Electronystagmography (ENG) showed bilaterally normal responses to caloric irrigation, no optokinetic nystagmus, normal gain but increased phase of the vestibulo-ocular reflex on rotational chair testing. Smooth pursuit was disturbed, as well as some saccades with increased latency. Because the progressive worsening of the gait instability, motor disturbances and ENG findings did not fit the fingerprint of a peripheral vestibular disorder, we referred the patient to the dept. of Neurology for further evaluation. Neurologic examination revealed trunk ataxia, choreatic limb movements, opsoclonus, oral dyskinesia, myoclonus, hyperreflexia and cerebellar speech. CT did not reveal any structural abnormalities, while a small posterior cerebellar infarction was observed on a repeat MRI. Family history of similar (milder) symptoms suggested Huntington's disease. Genetic testing on blood samples demonstrated 36 CAG repeats in the Huntingtin gene, leading to a definite diagnosis of Huntington's disease.

### **Conclusion**

Huntington disease is a progressive disorder of motor, cognitive, and psychiatric disturbances. In this particular case, the patient presented with balance symptoms that might be consistent with a peripheral as a central vestibular disorder. The oculomotor findings in Huntington include saccadic disturbances in initiation, speed and suppression, and impaired smooth pursuit. These findings can be observed while maintaining an intact vestibulo-ocular reflex.

## **“La goutte au nez”: a rare case of nasal gouty tophus presenting with nasal obstruction and nasal hump.**

*P. Levie, W. Renwart*

SARE ( chirec), Anderlecht, Belgium

### **Introduction and aim**

Gout is a well-known pathology caused by a disordered metabolism of purine with accumulation of monosodium urate crystals mainly in peripheral joints. It strikes mostly the first metatarsal-phalangeal joint with a peak age incidence of 30-50-year-old men. The pathology presents as a recurrent inflammation with intercurrent symptom free periods. Nevertheless, the expression of this disease can be found on the entire body by a gouty nodular formation.

The nasal gouty tophus has been described several times but stays a rare expression of a common disease. However, the symptoms resulting of this rare expression are as banal as nasal hump and nasal obstruction.

By this case-report we highlight the necessity of a thorough clinical examination and a large differential diagnosis for recurrent or persistent nasal hump.

### **Case report**

A 53-year-old man with no gouty arthritic history presents at consultation for nasal obstruction. Medical examination and complementary tests concluded on both right nasal septum deviation associated with a rhinitis medicamentosa, therefore a local corticoid therapy was started. The check-up consultation at 2 months showed a limited clinical improvement. Furthermore, a hump was described on the middle third of the nasal dorsum.

A rhinoseptoplasty was performed with immediate results on the nasal breathing and a satisfying aesthetic outcome. Nonetheless, at 3-month follow-up the patient perceived a recurrence of the nasal hump. Therefore, a second rhinoplasty was made where the reluctant fibrotic material was removed and analysed. Anatomopathological analysis confirmed a nasal gouty tophus. After rheumatologic consultation allopurinol, colchicine and feldene were started with success on the nasal symptoms.

### **Conclusions**

This case-report demonstrates that a common disease through his rare expression can lead to banal symptoms such as nasal hump and nasal obstruction. Therefore, a well-treated patient with recurrence or atypical symptomatology, such as local inflammation should benefit of an extended differential diagnosis.

## **Titel**

*M. Hoste*

UCL

### **Background**

Congenital neck anomalies represent more than half of cervical masses surgically treated in children. Of these, Thyroglossal Duct Cyst (TGDC) is the most commonly observed, representing 50 % of congenital anomalies. Typically, TGDC is clinically suspected in children with a median pre or subhyoid mass in the neck, mobile to swallowing and tongue protraction. However some clinical presentations are less usual.

### **Patients**

We report three cases with unusual presentation of TGDCs. The first patient presented as a bony fusion between the hyoid bone and the thyroid cartilage. The second patient was mimicking a second branchial cleft fistula. The third patient presented with multicystic lesion invading in the preepiglottic space.

### **Results**

Despite atypical presentations, good outcomes were observed after surgery requiring adapted procedure.

### **Conclusions**

Atypical presentation of THGD is rare but should not be overlooked. When the diagnosis is suspected preoperatively, the Sistrunk's procedure with resection of the body of the hyoid bone and the TG tractus up to the tongue base is necessary to avoid recurrence.

## **Post-irradiated carotid blowout syndrome in patients with nasopharyngeal tumor: about 3 cases**

*V. Detroux<sup>1</sup>, Y. Goffart<sup>2</sup>, Al. Poirrier<sup>1</sup>, D. Maris<sup>2</sup>, L. Collignon<sup>3</sup>, PP Lefebvre<sup>1</sup>*

<sup>1</sup>ENT Department, CHU Sart-Tilman, Liege, Belgium, <sup>2</sup>ENT Department, CHR Citadelle, Liege Belgium, <sup>3</sup>Radiology department, CHR Citadelle, Liege, Belgium

### **Introduction**

Rupture of the internal carotid artery (Carotid blowout syndrome) is a rare complication of irradiated nasopharyngeal tumor.

We report three cases nasopharyngeal tumors treated with radiotherapy complicated with bleeding of the internal carotid artery presenting as a massive epistaxis.

### **Case Series**

The first case presented a few episodes of small nose bleeding before a massive one. Internal carotid embolisation was performed to stop the bleeding. Unfortunately, few month later, he presented a meningitis related to skull base osteoradionecrosis and died from septic shock.

The second case was transferred to our hospital with severe repetitive epistaxis that had been occurring for hours. No endovascular treatment was possible in his case and he died in intensive care unit the day of his admission.

The third case presented one massive epistaxis which stopped without any treatment or compression. A spontaneous occlusion of his internal carotid artery occurred without any neurological defects. He recently benefited from a nasopharyngeal muscle flap for the coverage of the osteoradionecrosis.

These three patients all presented with a history of nasopharyngeal tumor handled by radiotherapy. Pathogenesis, treatment, and outcome are discussed on the light of a comprehensive literature review.

### **Conclusions**

Carotid blowout syndrome secondary to radiation therapy is rare but life-threatening. Re-irradiation and skull base osteoradionecrosis are strong predisposing factors.



## **Flexible rhinolaryngoscopy in infant: indications, conditions of execution, complications**

*A. Hanot, J.-C. Degols, E. Holvoet*

Service ORL, Clinique Saint Pierre, Ottignies, Belgium

### **Introduction and aim**

Pharyngolaryngeal fibroscopy is routinely used by otolaryngologists. The goal of this study was to evaluate in a daily practice the indications, procedures and potential complications in infants.

### **Methods**

We send a questionnaire to 30 ENT teams from Belgium and neighboring. 11 physicians completed their questionnaire. Some of them were re-contacted when precisions were needed. In cases we found different practices among physicians, an overview of the literature was realized.

### **Results**

There is an agreement among physicians to assess by endoscopy the following symptoms : stridor, dyspnea, dysphonia. However, dysphagia, suspicion of gastroesophageal reflux or obstructive sleep apnea were not systematically investigated by endoscopy. The fibroscopy is usually conducted in the office according to standard procedures : patient seated, using nasal path, no anesthesia nor empty stomach. When it is executed in these conditions, complications are rarely reported and benign. In some selected cases (as in patients with co-morbidities, risk of intubation,..), the procedure is preferably conducted in the operating quarter.

### **Conclusion**

In a daily practice, pharyngolaryngeal fibroscopy is a safe procedure to assess the aerodigestive tract in infant. There is no consensus on its contribution to diagnosis of gastroesophageal reflux.

## **Watch out for the great mimicker: a case series of primary syphilis in ENT practice**

*B. Pauwels, T. Cammaert, G. De Vos, P. Heylbroeck, P. Neyt, C. Vanclooster, P. Van der Eecken, S. Delrue*

Department of Otorhinolaryngology, Head and Neck Surgery, AZ Sint-Lucas, Gent, Belgium

### **Introduction and aim**

Although syphilis is now a much smaller public health threat in comparison to the early 20th century, a striking increase of *Treponema pallidum* infection has been reported over the last years. In the head and neck region, the lips are the most common site of spirochete inoculation. Chancre formation of the tongue and tonsils may also occur. The aim of this case series study was to describe the presentation of primary syphilis infection in ENT practice, and to increase the awareness of the disease.

### **Material and methods**

Retrospective single-center case series of all patients diagnosed with primary syphilis between 2011 and 2017.

### **Results**

Five consecutive cases (average age, 35 yr; 80% men) presented with a primary syphilis infection of the head and neck region. Three patients had an ulcerative lesion in the oral cavity, and one in the oropharynx (tonsil). Another patient had a recent history of a mucosal lesion, but only presented with a cervical lymphadenopathy. In one patient transition to secondary syphilis (generalized papular rash) occurred. All patients were treated with a single dose of 2.4 million IU of benzathine penicillin G.

### **Conclusions**

Primary syphilis often presents non-specifically. Early diagnosis requires a high index of suspicion and may prevent transmission to other patients and transition to a further phase.

## **A prospective audit of acute ENT activity in a teaching hospital**

*M. Goffinet, L. Atta, S. Delrez, A. Asimakopoulos, G. Bendavid, A. Delhez, F. Rogister, PP. Lefebvre, AL. Poirrier*

ENT Department, University Hospital of Liege, Liege, Belgium

### **Introduction and aim**

Acute ENT coverage is available out-of-hours in most hospitals. However, increasing pressure to reduce healthcare cost threatens this service provision round the clock. Our goal was to audit the emergency ENT activity in our institution over a one-month period

### **Material and methods**

A prospective audit for all ENT referrals from the emergency department was carried out from May 1st to May 31st 2017. Descriptive statistics were produced for age, sex, origin, time of arrival, diagnosis and patient outcome.

### **Results**

A total of 190 patients (109 men and 81 women) were referred to the ENT emergency service over the study period (mean 6.1 case per day). Mean age was 47.9 ( $\pm$  23.6) year (range 1-95). Most patients were ambulatory (75.8%) and came from the area. Most admissions occurred during normal working hours (76.4%) and 62.0% patients came by self reference. The mean complaint duration before admission was 7.6 ( $\pm$  13.7) days (range 0-92 days). One third (33.2% patients) required ambulatory treatment. A quarter (24.7% patients) underwent a minor ENT procedure. Eighteen (9.5%) patients required admission to the ward (mostly for intravenous antibiotic). Eight patients (4.2%) required surgical treatment. There was no difference in the severity of diagnosis or management between patients referred by a physician (GP or specialist) and patients presenting spontaneously. At 30 days, 3 (1.6%) patients died (one of ENT cancer, two of unrelated cause), 106 (55.8%) benefited from an ENT follow'up, 65 (34.2%) were referred to another physician (GP or specialist), 16 (8.4%) were lost to follow'up.

### **Conclusions**

The workload suggests that emergency ENT activity is justified in our hospital. Restricting emergency ENT cover to patients referred by a GP or another physician would not allow for a better patient selection.

## Etiologies, and hearing status in 129 bilateral vestibulopathy patients

O. Peetermans<sup>1</sup>, B. Boon<sup>1</sup>, B. Dobbels<sup>1,2</sup>, J. De Belder<sup>1</sup>, S. Matthysen<sup>1</sup>, P. Van de Heyning<sup>1,2</sup>, G. Mertens<sup>1,2</sup>, V. Van Rompaey<sup>1,2</sup>

<sup>1</sup>Faculty of Medicine and Health Sciences, University of Antwerp, Antwerp, Belgium, <sup>2</sup>Dept. Otorhinolaryngology & Head and Neck Surgery, Antwerp University Hospital, Belgium

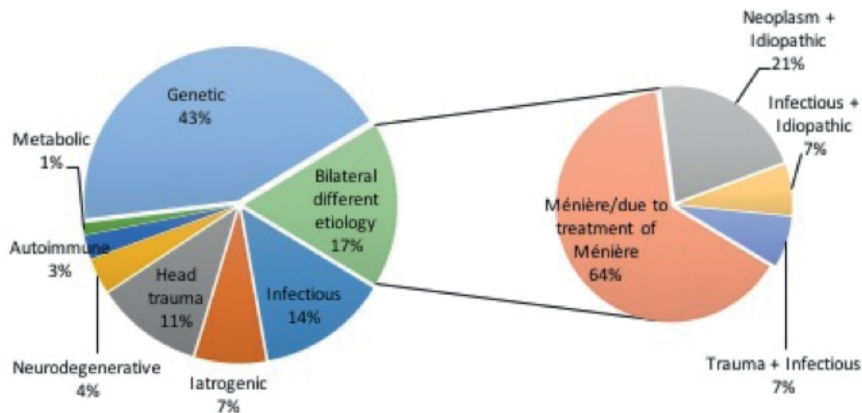
### Introduction and aim

Bilateral vestibulopathy (BV) is characterized by a bilateral partial or complete loss of function of the inner ear vestibular structures, the vestibular nerves or a combination of both. This condition presents itself mainly with impaired gaze fixation, also called oscillopsia.

Our primary aim was to determine the definite and probable etiology in BV patients. Our secondary aim was to report on the hearing status in these patients.

### Material and methods

A retrospective study was performed on consecutive BV patients diagnosed and followed in a tertiary referral center (UZA) between 2004 and 2018. The 2017 diagnostic criteria of the Barany society were used: (1) reduced caloric response: sum of bithermal maximum slow phase velocity on each side < 6°/sec. and/or (2) reduced horizontal angular vestibulo-ocular reflex gain < 0,1 upon sinusoidal stimulation on a rotatory chair.



### Results

We identified 129 BV patients, 59% male. The mean age at diagnosis was  $57 \pm 15,6$  years (range 10-84 years). The definite cause was determined in 40% of patients and the probable cause in 23% of patients. No cause was identified in 37% of BV patients. The distribution of etiologies can be found in figure 1. In 17% of patients, a different etiology was identified on each inner ear. The largest subgroup included patients with a genetic etiology, most frequently DFNA9.

Of all patients, 22% had bilateral normal hearing to mild sensorineural hearing loss (SNHL) impairment, 12% had bilateral moderate to severe SNHL and 32% had bilateral profound SNHL. Furthermore, 22% of patients presented unilateral deafness and 7% unilateral moderate to severe SNHL.

### Conclusion

Bilateral vestibulopathy is a heterogeneous condition, with over 1/3 of cases remaining idiopathic, and more than 3/4 affected by hearing loss. DFNA9 is the most common cause of BV in our population.

## **Does otovestibular loss in DFNA9 have an impact of on cognition? A systematic review**

*S. Matthysen<sup>1</sup>, J. De Belder<sup>1</sup>, A. Claes<sup>1,2</sup>, G. Mertens<sup>1,2</sup>, P. Van de Heyning<sup>1,2</sup>, V. Van Rompaey<sup>1,2</sup>*

<sup>1</sup>Faculty of Medicine and Health Sciences, University of Antwerp, Belgium, <sup>2</sup>Dept. Otorhinolaryngology & Head and Neck Surgery, Antwerp University Hospital, Belgium

### **Introduction and aim**

Cognitive impairment has been observed in patients with bilateral vestibulopathy (BV) and in patients with sensorineural hearing loss (SNHL). DFNA9 is an autosomal dominant disorder that causes a combination of both sensory deficits by the 3rd to 5th decade. We therefore hypothesize a combined detrimental effect on cognition.

The aim of this systematic review was to identify studies related to DFNA9 in general and its relationship with cognitive impairment more specifically.

### **Material and methods**

Several databases including Medline, Cochrane Database of Systematic Reviews, Cochrane Central Register of Controlled Trials, ISI Web of Knowledge, and Web of Science were searched to accumulate information about DFNA9-mutations, including phenotype, genotype, pathophysiology, quality of life and imaging in general and cognitive function more specifically. A qualitative analysis was performed on the 55 articles that qualified.

### **Results**

The clinical features of DFNA9 are different along the 24 COCH mutations, described up to now. Vestibular symptoms generally present themselves a few years after SNHL onset in mutations associated with the vWFA-domain although they can precede SNHL onset in other mutations associated with the LCCL-domain. Quality of life (QoL) has not been studied extensively in DFNA9, although scarce work is available on the positive impact of cochlear implantation to rehabilitate hearing. No studies were found evaluating cognition in DFNA9 patients.

### **Conclusion**

Although cognitive impairment has been demonstrated in patients with hearing loss as well as in patients with bilateral vestibular loss, no studies have been reported on the combination of both sensory deficits, such as in DFNA9. Further research is warranted to correlate otovestibular status with cognition.

## **Aggregating the symptoms of superior semicircular canal dehiscence syndrome: review to develop evidence-based symptom set**

*L. Naert<sup>1</sup>, P. Van de Heyning<sup>1,2</sup>, R. Van de Berg<sup>2,3</sup>, B. Ward<sup>4</sup>, A. Bisdorff<sup>5</sup>, J. Sharon<sup>6</sup>, V. Van Rompaey<sup>1,2</sup>.*

<sup>1</sup>Faculty of Medicine and Health Sciences, University of Antwerp, Belgium, <sup>2</sup>Dept. Otolaryngology–Head & Neck Surgery, Antwerp University Hospital, Belgium, <sup>3</sup>Dept. Otolaryngology, Head & Neck Surgery, Maastricht University Medical Center, the Netherlands, <sup>4</sup>Dept. Otolaryngology, Head & Neck Surgery, Johns Hopkins University School of Medicine, USA, <sup>5</sup>Dept. Neurology, Centre Hospitalier Emile Mayrisch, Esch-Alzette, Luxemburg, <sup>6</sup>Dept. Otolaryngology, Head & Neck Surgery, University of California, San Francisco, USA

### **Introduction and aim**

Superior canal dehiscence syndrome (SCDS) was first described by Lloyd Minor in 1998. An absence of bone overlying the superior semicircular canal creates a third mobile window into the inner ear in addition to the oval and round windows. When patients report their symptoms are causing significant impairments to their quality of life (QoL), surgeons have offered a variety of surgical procedures. Comparing the effectiveness of these procedures, however, is challenging, as there is no patient-reported outcome measure (PROM) designed specifically for evaluating SCDS-specific health-related QoL. The aim of this study was to perform a systematic review of all symptoms reported by patients with SCDS, with the broader goal of enabling the eventual design of a condition-specific PROM.

### **Material and methods**

Medline and PubMed databases were searched for articles that reported the preoperative symptoms of adult and pediatric patients with unilateral and bilateral SCDS. Articles were excluded if they reported on associated diseases or did not report symptoms.

### **Results**

Of the 397 articles retrieved, 66 were retained for quantitative analysis. Among 431 patients with SCDS, 1,253 symptoms were identified and 91 symptom terms were reported. After combining synonymous terms, 22 symptoms were derived by consensus. Of the raw total number of reported symptoms 92.5% can be attributed to 5 common symptoms: spontaneous dizziness (51%), autophony (42.5%), pressure-induced vertigo (37.4%), hearing loss (39.9%) and sound-induced vertigo (42.7%).

### **Conclusion**

This systematic review of symptoms reported by patients with SCDS identified a 22-item common symptom set. The 5 most frequently reported symptoms were spontaneous dizziness, sound-induced vertigo, autophony, hearing loss and pressure-induced vertigo. The items derived from this study can be used as the initial steps toward creating a novel validated PROM in patients with SCDS.

## **Sigmoid sinus diverticulum/aneurysm in a patient with incapacitating pulsatile tinnitus**

*V. Verkest<sup>1</sup>, P. Van de Heyning<sup>1,2</sup>, V. Van Rompaey<sup>1,2</sup>*

<sup>1</sup>Dept. Otorhinolaryngology & Head and Neck Surgery, Antwerp University Hospital, Belgium, <sup>2</sup>Faculty of Medicine and Health Sciences, University of Antwerp, Belgium

### **Introduction and aim**

Pulsatile tinnitus can impose a significant burden upon quality of life. It is characterized by rhythmic pulsations synchronous to the patient's heartbeat, discriminating venous hum from its arterial analogue by its continuous murmur and the abolishment of symptoms when compressing the ipsilateral jugular vein. Pulsatile tinnitus might be caused by the increased sensitivity to bone-conducted sounds (such as in superior semicircular canal dehiscence syndrome) or disruption of laminar flow, creating audible turbulence. The latter might be caused by sigmoid sinus anomalies (incl. diverticulum, aneurysm, wall dehiscence, etc.), by increased cardiac output syndromes (incl. anemia, hyperthyroidism, pregnancy, etc.) or intracranial hypertension.

We report the case of a patient who presented at our department with an incapacitating venous pulsatile tinnitus in the right ear.

### **Case report**

A 55-year-old woman presented at the outpatient clinic with an incapacitating venous hum in her right ear for 2 years, with sleep disturbances. Tinnitus Functional Index revealed a severe level of distress (score of 70.4). Occluding her ipsilateral jugular vein made this noise stop immediately. She did not report any other otological symptoms, such as hearing loss or vertigo. Microscopic examination of the tympanic membrane was normal. Liminal and speech audiometry thresholds were normal. The patient had a history of Becker Muscular Dystrophy and hypothyroidism. She took L-thyroxine, Promagnor, Paroxetine, Zolpidem and Alprazolam. Echocardiography demonstrated a normal cardiac output.

High-resolution temporal bone CT and MRI angiography showed a laterally protruding sinus sigmoid diverticulum/aneurysm in the right mastoid with a focal wall dehiscence. Due to the incapacitating complaints and sleep disturbance of the patient we advised to perform surgical reconstruction.

During surgery, the lesion appeared to be a well-circumscribed sac in which the sigmoid sinus focally protruded into the adjacent mastoid area, more likely to be sigmoid sinus aneurysm. The wall dehiscence on the anterosuperior aspect towards the junction with the superior petrosal sinus was also identified. The sigmoid sinus along with the aneurysm were skeletonized, decompressed and pushed medially. The cortical bone was reconstructed in this new position with cortical bone chips and bone paté obliterating the mastoid fully. Prophylactic low-molecular weight heparines were administered to prevent venous thrombo-embolism. In the postoperative period, the patient experienced symptom relief from the day after surgery and onwards.

### **Conclusion**

Pulsatile tinnitus as a result of sigmoid sinus diverticula, aneurysms and dehiscence is a rare, but largely treatable condition. Available interventions include sigmoid sinus wall reconstruction with cortical bone chips and bone paté which has a high rate of symptom resolution.

## Genotype and phenotype correlation of transgenic *Coch* mouse models

A. Liesenborghs<sup>1</sup>, K. Goyvaerts<sup>1</sup>, D. De Herdt<sup>1</sup>, P. Van de Heyning<sup>1,2</sup>, G. Van Camp<sup>3</sup>, P. Ponsaerts<sup>4</sup>, V. Van Rompaey<sup>1,2</sup>

<sup>1</sup>Faculty of Medicine and Health Sciences, University of Antwerp, Belgium, <sup>2</sup>Dept. Otorhinolaryngology & Head and Neck Surgery, Antwerp University Hospital, Belgium, <sup>3</sup>Dept. Medical Genetics, University of Antwerp, Belgium, <sup>4</sup>Lab. Experimental Hematology, University of Antwerp, Belgium

### Introduction and aim

DFNA9 (DeafNess Autosomal dominant 9) is a form of late-onset, progressive, non-syndromal, autosomal dominant disorder leading to progressive bilateral vestibulopathy first and deafness later on. Missense mutations in the *COCH* gene – which is located on human chromosome 14 (mouse chromosome 12) and encodes for the protein Cochlin – are responsible for the pathologic features of this disorder. The P51S mutation is predominant in Belgium and the Netherlands. Animal models have been reported for the G88E *Coch* mutation, which has a similar human phenotype as P51S.

Our primary aim was to critically review genotype-phenotype correlations in all reported animal models for DFNA9 and compare them to the human phenotype.

### Methods

We used the query “(“rodentia”[Mesh] AND (DFNA9 OR Coch) NOT Coch[author] NOT cocaine hydrolase” in Pubmed. Twenty-five articles met the inclusion criteria and were critically reviewed.

### Results

The loss of Cochlear/vestibular sensory epithelia is comparable to wild type mice, both in homozygote knock-in *CochG88E/G88E* nor in knock-out *Coch*<sup>-/-</sup> mice. The characteristic Eosinophilic deposits were found in *CochG88E/G88E* but not in *Coch*<sup>-/-</sup> or wild-type mice.

Sensorineural hearing loss affected homozygote *CochG88E/G88E* (hearing loss across all frequencies), *Coch*<sup>-/-</sup> (high-frequency hearing loss) and heterozygote *CochG88E/+* (similar to wild-type).

Vestibular dysfunction was observed in *CochG88E/G88E* and *Coch*<sup>-/-</sup> mice. Onset occurred at a younger age in *CochG88E/G88E* than in *Coch*<sup>-/-</sup> mice. No vestibular dysfunction was observed in heterozygote *CochG88E/+* or wild-type mice. Vestibular dysfunction has consistently been observed before the onset of sensorineural hearing loss in all mouse models.

No transgenic P51S mouse model was identified.

### Conclusion

The auditory and vestibular phenotype in the homozygote *CochG88E/G88E* mice resembles the DFNA9 phenotype the most. However, DFNA9 in humans is provoked by a heterozygote mutation in the *COCH* gene. In contrast, the heterozygote *CochG88E/+* mice present with similar sensorineural hearing loss as wild-type mice and no vestibular dysfunction. Currently, no transgenic P51S mouse model is available, that would enable fundamental research into the mutation most frequently causing DFNA9 in Belgium and the Netherlands.



## **An unusual soft tissue tumor in the pterygopalatine fossa**

*SD. Le Bon, A. Rodriguez, M. Horoi*

CHU Sint-Pieter, Brussels, Belgium

### **Introduction**

Eosinophilic angiocentric fibrosis (EAF) is a very rare and poorly understood inflammatory disease that affects the upper respiratory tract, mainly involving the nose and the sinuses. When possible, tumor resection is the recommended line of treatment. Otherwise, corticosteroid therapy is the only alternative described in the literature.

### **Case report**

A 30 year-old male of Turkish origin first presented in May 2017 to the emergency room for a history of 10 kg weight loss in 3 months, cough, dyspnea and general fatigue. He was later hospitalized twice in July and September for recurrent pleuropneumonia. Inpatient work-up showed pulmonary nodules and splenomegaly, while excluding other diagnoses as tuberculosis and pulmonary cancer. In October, a head CT for a recent right eyelid ptosis revealed a mass in the right pterygopalatine fossa, extending to the orbit and the maxillary sinus. A biopsy through the posterior wall of the right maxillary sinus was performed by endoscopy under general anesthesia. The pathological examination showed many eosinophils with thick collagen bundles whorling around vessels, without malignant cells, necrosis or granuloma, suggesting the diagnosis of EAF. We present a review of masses that can be found in the pterygopalatine fossa.

### **Conclusions**

The pterygopalatine fossa is a rare location for tumors. Our case report is one of a few cases of EAF in the pterygopalatine fossa. Although exceptional, EAF needs to be mentioned in the differential diagnosis of sinonasal and pterygopalatine masses of unclear etiology.

## **A rare cause of deafness (in a 24 yo musician)**

*M. Samaha, M. Horoi, C. Ducène, MP. Thill*

University Hospital St-Pierre, ULB, Brussels

### **Introduction**

The vestibule is a rare localisation for schwannomas. We report a case of intravestibular schwannoma in a young patient.

### **Case report**

A 24 year-old male musician presented with left sensorineural hearing loss of 40 dB and fluctuating tinnitus. Temporal CT scan was normal but MRI with contrast revealed a 4-millimeter left intravestibular schwannoma. Although the patient did not complain of dizziness nor vertigo, vestibular examination revealed a left areflexia. Wait-and-scan attitude was recommended. 7 years later, the patient presented with left cophosis. MRI showed that the tumor volume had doubled. Surgical treatment was performed by translabyrinthine approach as the schwannoma extended to the lateral and superior semicircular canals.

### **Discussion**

There are only around 350 cases of intralabyrinthine schwannomas described in the literature, among which 10% originate in the vestibule without extending to the cochlea. Clinical presentation may include sensorineural hearing loss, vertigo, tinnitus or a combination of these symptoms. In case of persistent or transient sudden hearing loss, MRI with contrast is the recommended first imaging study. Excision can be done either through the ear canal, even endoscopically, or by a translabyrinthine approach if there is an extension to the semicircular canals. Cochlear implants could be indicated.

### **Conclusion**

Surgical indication depends on the intensity of cochleovestibular symptoms and growing rate of the tumor, while surgical approach depends on tumor localisation.

## **The Repeatable Battery for the Assessment of Neuropsychological Status for Hearing impaired individuals (RBANS-H) in an older population with age-normal hearing**

*A. J. Claes<sup>1,2</sup>, G. Mertens<sup>1,2</sup>, A. Gilles<sup>1,2,3</sup>, T. Dom<sup>3</sup>, N. Janssen<sup>2</sup>, J. Janssens<sup>2</sup>, A. Hofkens-Van den Brandt<sup>1</sup>, P. Van de Heyning<sup>1,2</sup>, V. Van Rompaey<sup>1,2</sup>*

<sup>1</sup>Univ. Dept. Otorhinolaryngology & Head and Neck Surgery, Antwerp University Hospital, Belgium, <sup>2</sup>Exp. Lab of Translational Neurosciences and Dento-Otolaryngology, Faculty of Medicine and Health Sciences, University of Antwerp, Belgium, <sup>3</sup>Dept. of Human and Social Welfare, University College Ghent, Belgium

### **Introduction and aim**

Hearing loss is independently associated with accelerated cognitive decline and dementia. Whether hearing loss is a biomarker for early stage dementia or rather a modifiable risk factor for dementia remains to be studied. Validated outcome measures are available to evaluate cognition in older adults. However, cognitive functioning may be underestimated due to age-related hearing loss, since they assume normal auditory capabilities. Therefore, the Repeatable Battery for the Assessment of Neuropsychological Status for Hearing impaired individuals (RBANS-H) has been developed, which is an adaptation of the RBANS, a validated cognitive assessment tool. The RBANS-H provides additional visual support to the examinee by means of an external screen. The age-corrected RBANS total score is scaled to a normal distribution with a mean of 100 and a standard deviation of 15. The aim of the study is to investigate whether the normative data of the original RBANS are valid for use in the adapted RBANS-H.

### **Material and methods**

Eighty-two subjects (40 male, 42 female) were included in the study with a mean age of 69 years (range 50-87 years) and with hearing thresholds normal for their age and sex. The RBANS-H was administered.

### **Results**

The mean RBANS-H total score was 100.09. A one-sample t test with test value 100 (i.e. the mean norms score of the RBANS) indicates no difference between the obtained scores with the RBANS-H and the RBANS norm data ( $p=0.951$ ).

### **Conclusion**

Normative values for RBANS may be used for score calculation and interpretation of the RBANS-H.

## **Osteoblastoma of maxillary sinus and hard palate: a case report**

*E. Oorts<sup>1</sup>, C. Cox<sup>1</sup>, K. Deben<sup>1</sup>, A-S. Eeckels<sup>1</sup>, S. Janssens de Varebeke<sup>1</sup>, J. Jacobs<sup>2</sup>, T. Cox<sup>1</sup>*

<sup>1</sup>Department of Otorhinolaryngology and Head & Neck Surgery, Virga Jessa Hasselt, Belgium, <sup>2</sup>Department of Maxillofacial Surgery, Virga Jessa Hasselt, Belgium

### **Introduction and aim**

Osteoblastoma is a rare benign bone-forming tumor accounting for less than 1% of all primary bone tumors. Most frequently it affects the spine and long bones in contrast with the skull and facial bones which are rarely involved. We present a patient with an osteoblastoma localized in the left maxillary sinus and hard palate and its treatment.

### **Case report**

A 13-year-old boy presented with swelling at the left side of the hard palate and nocturnal pain. Initially a dental abscess was suspected by the general practitioner, hence a long-term antibiotic treatment was given, which was unsuccessful. The patient was referred to the maxillofacial surgeon, who performed a diagnostic puncture that didn't reveal any purulence. The absence of clinical improvement after long-term antibiotics and the negative puncture made the initial diagnosis of a dental abscess very unlikely. Subsequently a cone-beam CT was carried out, which showed a tumoral lesion of the left maxillary bone at the transition between the alveolar process of the maxilla and the hard palate. A palatal access via a mucoperiosteal flap was performed by the maxillofacial surgeon to take a biopsy. Histopathologic examination confirmed the diagnosis of osteoblastoma. We proposed a multidisciplinary (ENT – Maxillofacial surgery) treatment with a combined approach to obtain complete removal. A first access was made via endoscopic opening of the maxillary sinus through a middle meatal antrostomy, making a superomedial view possible. Secondly, a palatal access was made via the mouth through an opening in the alveolar process of the maxilla with a mucoperiosteal flap, which made an inferior view possible. Computer-assisted navigation was used during this surgery.

### **Discussion**

Involvement of the paranasal sinuses by osteoblastoma is rare. Treatment requires extensive surgical excision, because the biological behavior of osteoblastoma can be locally aggressive and malignant transformation into osteosarcoma is reported. We used a computer navigated combined approach to obtain complete surgical removal and avoid damaging the growth centers of the face.

### **Conclusion**

We present a rare case of osteoblastoma of the hard palate expanding to the maxillary sinus. Although it's a benign slow growing tumor, total removal with extensive surgical excision is needed because of its potential aggressive behavior.

## **A rare case of a complicated otomastoiditis: bezold abscess**

*A.-S. Eeckels, C. Cox, T. Cox, T. Crins, K. Ketelsslagers, E. Oorts, S. Janssens de Varebeke*

Department of Otorhinolaryngology and Head & Neck Surgery, Virga Jessa Hasselt, Belgium

### **Introduction and aim**

We report an unusual case of complicated chronic otitis media.

### **Case report**

A 52-year old female was transferred because of persistent purulent otorrhea and otalgia at the left ear for 6 months. The patient was given systemic and local ciprofloxacin with only temporarily improvement of the complaints. Otoscopic evaluation showed chronic otitis externa and media. Over the left mastoid process there was erythema, oedema, tenderness and induration expanding toward the upper half of the neck ipsilateral. A Bezold abscess was suspected. CT scan of the temporal bone showed severe opacification of the middle ear and coalescent mastoiditis with abscedation invading the upperside of the sternocleidomastoid and occipital muscles, confirming the diagnosis. There was a destruction of cortical bone at the level of posterior wall of the outer ear canal, which probably served as epithelial ingrowth zone to develop a large cholesteatoma towards the mastoid tip and neck. Immediate IV clindamycin and ciprofloxacin were administered and a large mastoidectomy with drainage of the abscess confirmed the presence of huge cholesteatoma, invading the whole mastoid. Peroperative cultures showed *Trueperella bernardiae* and anaerobes. *T. bernardiae* is an uncommon pathogen of opportunistic infections and its clinical implications are still unknown. The patient improved quickly and was discharged on hospital day 3. Oral ciprofloxacin and metronidazole was continued for 4 weeks.

### **Discussion and conclusion**

Bezold abscess is a rare complication of otomastoiditis in which pus erodes the mastoid inferomedial along the digastric and sternocleidomastoid muscles in the neck. This phenomenon occurs mostly at adult age especially when there is a history of cholesteatoma or mastoidectomy. Due to the depth of its location, the abscess can be impalpable and the diagnosis can be clinically missed. In our case the whole mastoid and upper neck region was indurated. If a Bezold abscess is suspected a CT scan is the best diagnostic tool (3,5). It is important to start urgent treatment with antibiotics and consider surgical drainage to avoid further complications. This case must remind us of the possibility of a Bezold abscess in the differential diagnosis of a retro-auricular mass expanding to the upper neck.

## **Case report: Use of Floseal™ for hemostasis during mastoidectomy**

*E. Oorts, K. Deben, K. Ketelslagers, T. Crins, S. Janssens de Varebeke*

Department of Otorhinolaryngology and Head & Neck Surgery, Virga Jessa Hasselt, Belgium

### **Introduction and aim**

In otologic surgery it is very important to have good visualisation. Therefore optimal hemostasis is of great importance at all times. We report the use of Floseal™ for hemostasis of a sigmoid sinus bleeding during mastoidectomy for cochlear implantation. Currently, there is a growing interest for Floseal™ for controlling nasal and sinus bleeding. To the best of our knowledge the use of Floseal™ in otologic surgeries has not yet been reported.

### **Case report**

A 24-year-old female with bilateral progressive sensorineural hearing loss underwent cochlear implantation on the right ear at our Otorhinolaryngology Department in 2016. A posterior tympanotomy was performed, however a tear of a very small diverticle of the jugular bulb resulted in profuse bleeding. To obtain hemostasis, Floseal™ hemostatic matrix was applied to the source of bleeding. Complete hemostasis was obtained nearly immediately, followed by a 10 minutes observation time for consolidation of the clotting activity. The bulk of the foam was removed from the mastoid cavity and middle ear, with special care to avoid removing the foam layer at the bleeding site. Despite the relatively narrow space at the bleeding site and round window, the implantation procedure could be continued. With this case experience, we demonstrate the effectivity of Floseal™ to obtain adequate and fast hemostasis when (venous) bleeding occurs during mastoidectomy. As for the safety of Floseal™, with regard to possible ototoxicity, no signs of ototoxicity in transtympanic Floseal™ administration were observed in vivo.

### **Conclusion**

Profuse intraoperative venous bleeding in the middle ear is a challenging problem, which sometimes obstructs the surgeon from finishing the planned intervention. In this case, because a tiny jugular bulb diverticle prevented further widening of the posterior tympanotomy, the relatively narrow and deep round window niche could have easily been blocked with the use of any other kind of hemostatic material and could have therefore obstructed further steps of the cochlear implantation. The foam matrix allows the surgeon to remove the bulk of the mass after achieving hemostasis to a very fine layer covering the bleeding site, enabling good visibility of the surgical field, even in narrow spaces.

## The vestibular implant: new ways of effect evaluation

*F. Lucieer<sup>1</sup>, R. van de Berg<sup>1,4</sup>, N. Guinand<sup>2</sup>, C. McCrum<sup>3</sup>, K. Meijer<sup>3</sup>, P. Willems<sup>3</sup>, M. Ranieri<sup>2</sup>, S. Cavuscens<sup>2</sup>, JP. Guyot<sup>2</sup>, H. Kingma<sup>1,4</sup>, A. Perez-Fornos<sup>2</sup>*

<sup>1</sup>Division of Balance Disorders, Department of Otorhinolaryngology and Head and Neck Surgery, Faculty of Health Medicine and Life Sciences, School for Mental Health and Neuroscience, Maastricht University Medical Center, Maastricht, The Netherlands, <sup>2</sup>Service of Otorhinolaryngology and Head and Neck Surgery, Department of Clinical Neurosciences, Geneva University Hospitals, Geneva, Switzerland, <sup>3</sup>Faculty of Human Movement Sciences, Maastricht University Medical Center, Maastricht, The Netherlands, <sup>4</sup>Faculty of physics, Tomsk State University, Tomsk, Russia

### Introduction and aim

The vestibular implant (VI) is able to (partially) restore the vestibulo-ocular reflex, vestibulo-collic reflex, dynamic visual acuity and perception in humans. However, effects of the VI have only been evaluated by measuring reflexes and perception until now. Purpose of this study was to investigate the feasibility of using gait analysis for effect evaluation of the VI.

### Materials and methods

Two different substudies were performed on the CAREN Extended system (Motekforce Link, Amsterdam, The Netherlands). Firstly, gait characteristics of nine patients with bilateral vestibulopathy were examined at different walking speeds after familiarisation trials. Secondly, gait characteristics of two patients with bilateral vestibulopathy fitted with a VI, were examined at comfortable walking speed, using different stimulation conditions (baseline stimulation, positive modulation, negative modulation).

### Results

In the first group, certain gait characteristics in the sagittal plane improved with increases in walking speed (stride length, stride time, step length, double support time;  $P < 0.001$ ), however motions in the frontal plane (step width) became more variable ( $P = 0.003$ ). In the VI-patients, stride time, step time and step length improved when using positive modulation in both VI-patients. Step width decreased in one patient in the same condition.

### Conclusion

Patients with bilateral vestibulopathy show different gait patterns at different walking speeds, of which some might have implications for risk of falling. The VI is able to acutely alter certain gait characteristics. Therefore, it seems feasible to use gait analysis as an additional new tool for effect evaluation of the VI.

## The Caduceus

J. Tainmont

Queen Astrid Military Hospital Brussels and Erasmus Academic Hospital, ULB (Honorary)

### Introduction and aim

Physicians give the name of Caduceus to the symbol of Medicine, but the things are more complex. It is necessary to distinguish the Caduceus of Hermes and the stick of Asklepios

### Material and methods

The Caduceus of Hermes was the stick of herald which he carried as a spokesperson of Zeus. This badge made him inviolable. It was named *kerukion* in Greek, from *kèrux* “the cock” in a figurative sense.

This stick was furnished with snakes. This was justified by Archaeology. It was found that two snakes were associated with a tree branch as a symbol of the god of the vegetation. Both the tree and the snakes indeed were the emanation of the ground-mother.

Mythology was given the responsibility to explain the presence of two snakes by telling that Hermes, while walking, separated two snakes which fought one against the other.

Mythology again: wings were given to Hermes by Zeus when he became the messenger of the Gods, so that they accelerated his course.

For Asklepios, Mythology was different: he overcame an isolated snake which consequently became his devoted servant.

Next, Iconography added the mirror of Prudence to his stick so that Asklepios was capable of introspection and at the same time could take account of the experiment of the past, by using the mirror like a rear view mirror.

Lastly, Iconography added the sheets of a bay-tree, as civil virtues, and the sheets of an oak as military virtues, to the stick of Asklepios.

### Result and conclusion

Even if according to Archaeology, the Caduceus of Hermes and the stick of Asklepios have a stick and a snake in common, Mythology and Iconography differentiate them clearly.